

# 폐암의 영상 소견:

흉부 X 선을 중심으로

建國大學校病院  
影像醫學科  
李定根

Let's Enjoy 닥터 와이 폐영상

# 과거 “폐암 영상 소견” ; 주로 X ray, not CT

1. Central & peripheral type; 전통적
2. Cell type에 따라; 약간의 특징
3. TNM staging; CT 소견

## 지금 X-ray 모습

1. 화질 좋다; large airway 가 “꽤” 보인다
2. Level, width를 내가 조절
3. CT 찍기 쉽다; 고민 少
4. 예전 사진 많아 비교가 쉽다

폐암 소견 “결론”; 거의 모든 소견

“ $\alpha \sim \Omega$ ”

1. 동그랑; 알갱이-덩어리
2. 허영다; 열은 것-진한 것

1. Nodule ; Micronodule < Nodule < Mass
2. Air space opacity ; GGO < consolidation

Let's Enjoy 닥터 와이 폐영상

# 순서

고전적,

A. Central type

B. Peripheral type

私見; 의미 > 소견

C. “Missed” lung cancer

D. New or Grow : 비교

**Let's Enjoy 닥터 와이 폐영상**

# 순서

**A. Central type**

**B. Peripheral type**

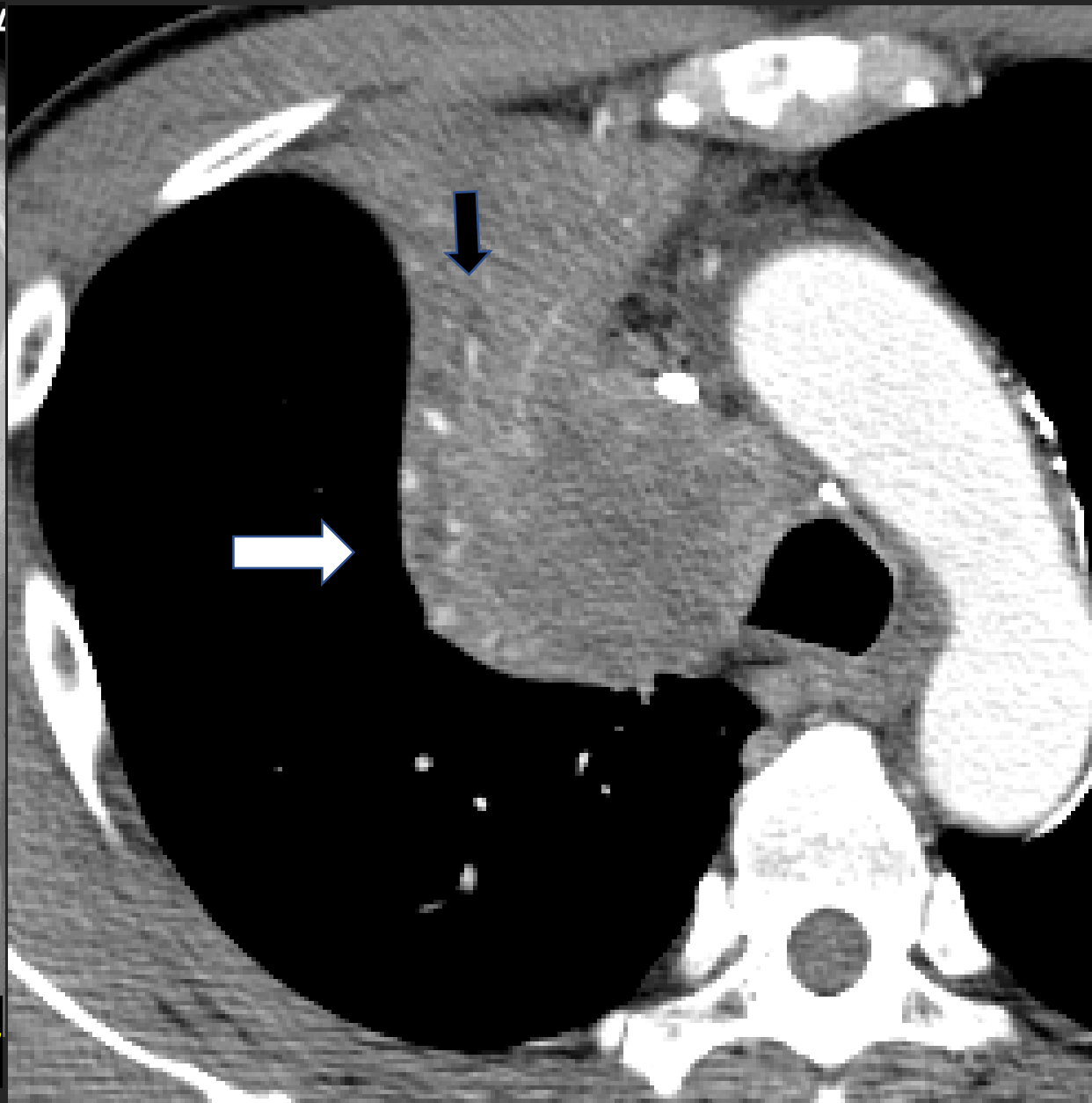
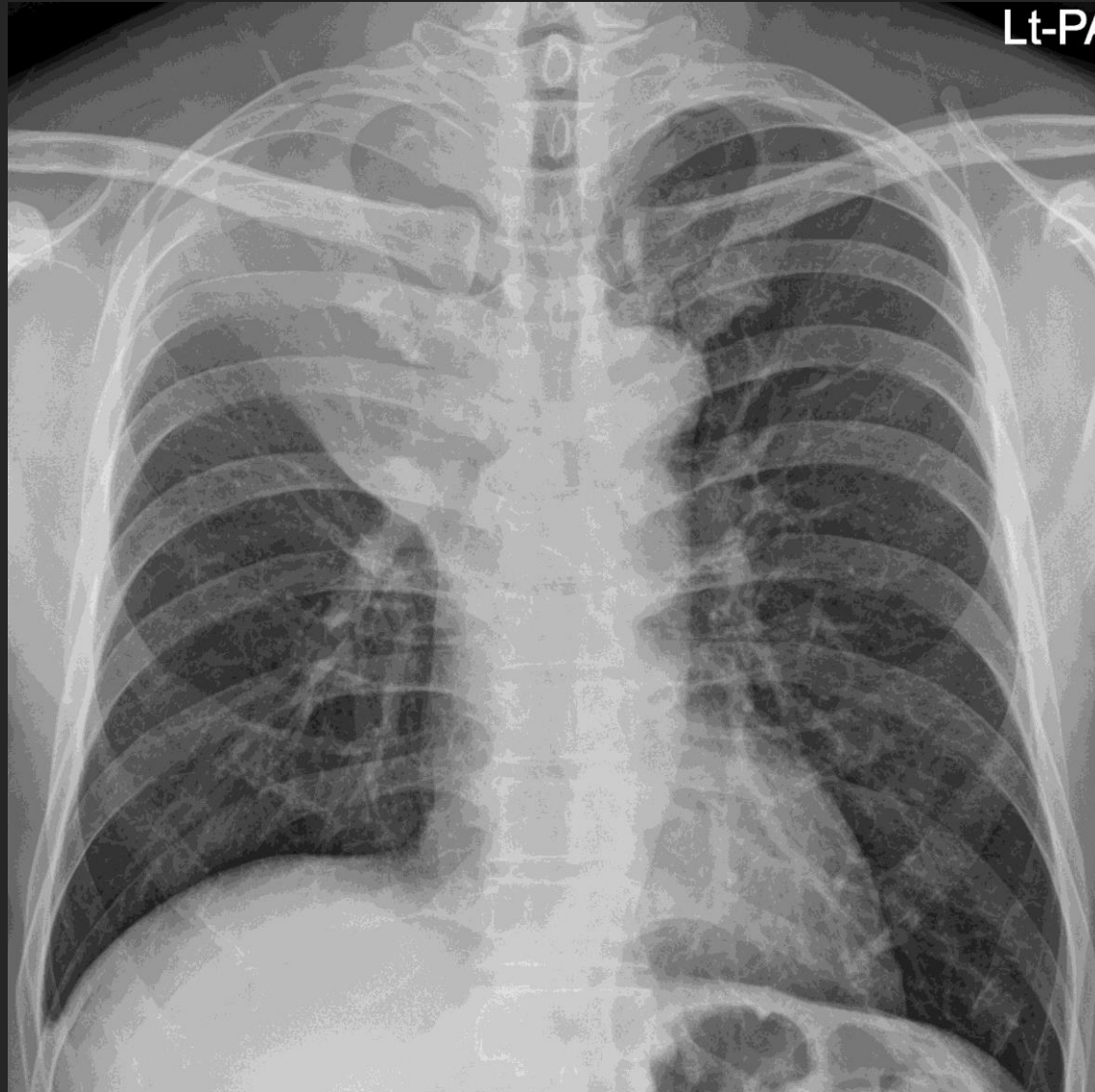
**C. “Missed” lung cancer**

**D. New or Grow : 무섭다**

## A. 가운데 폐암, Central type

- a. Obstructive pneumonitis
- b. Fluid/mucous bronchogram
- c. Mediastinal mass ( LN enlargement )
- d. Bronchial wall thickening

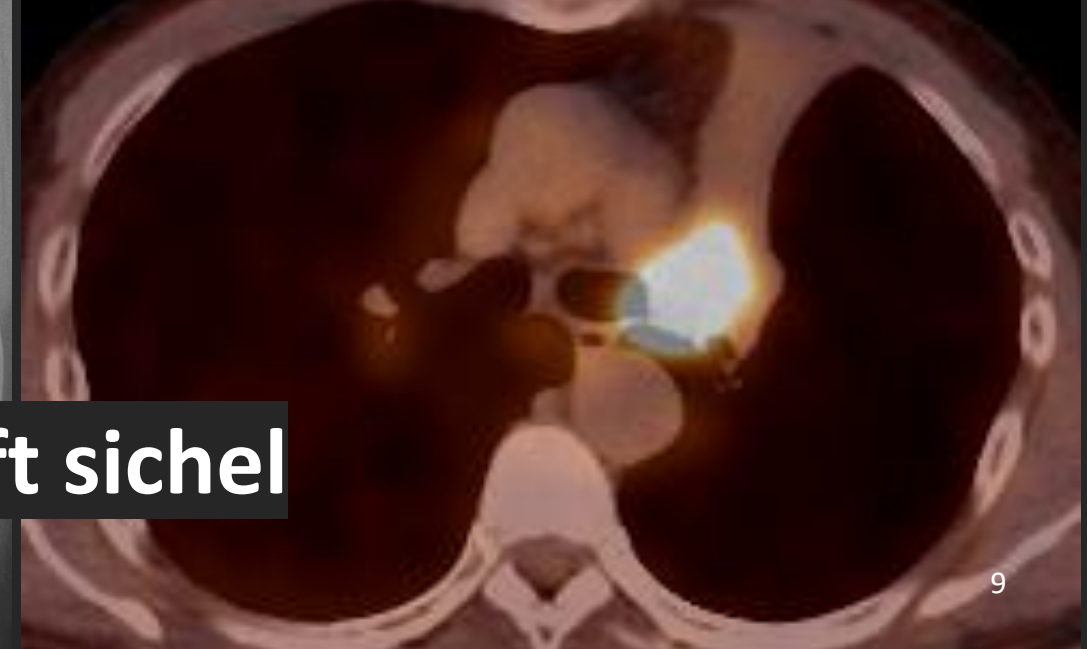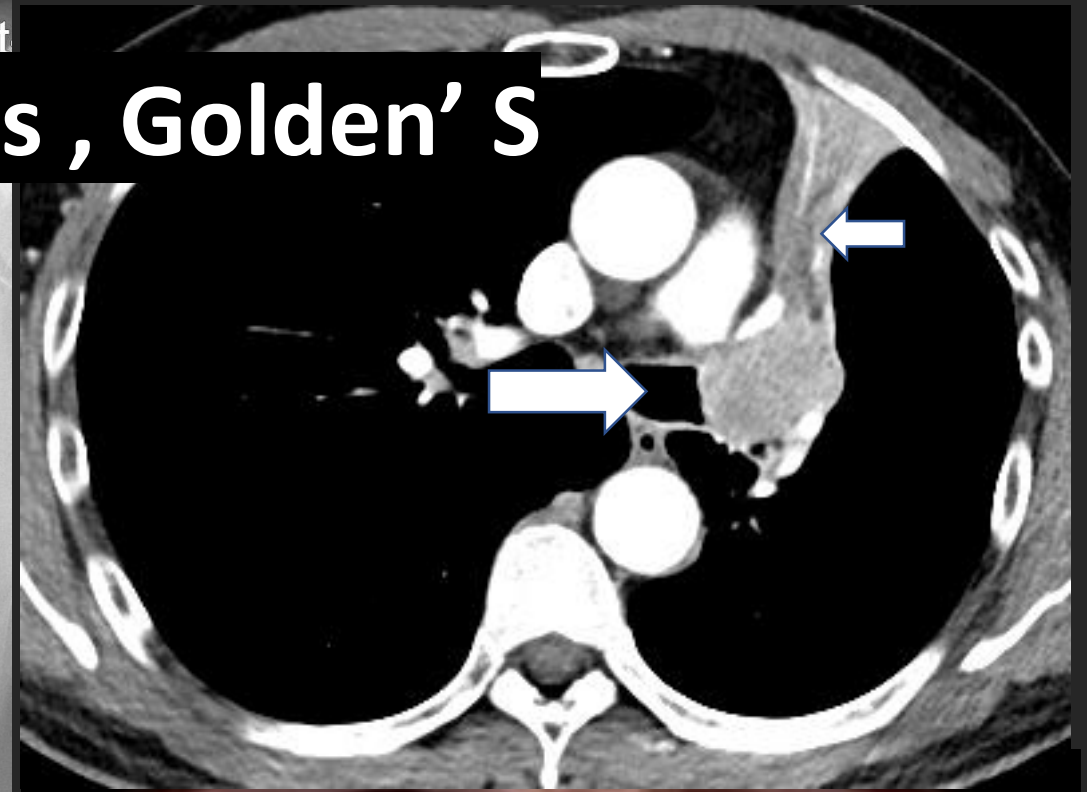
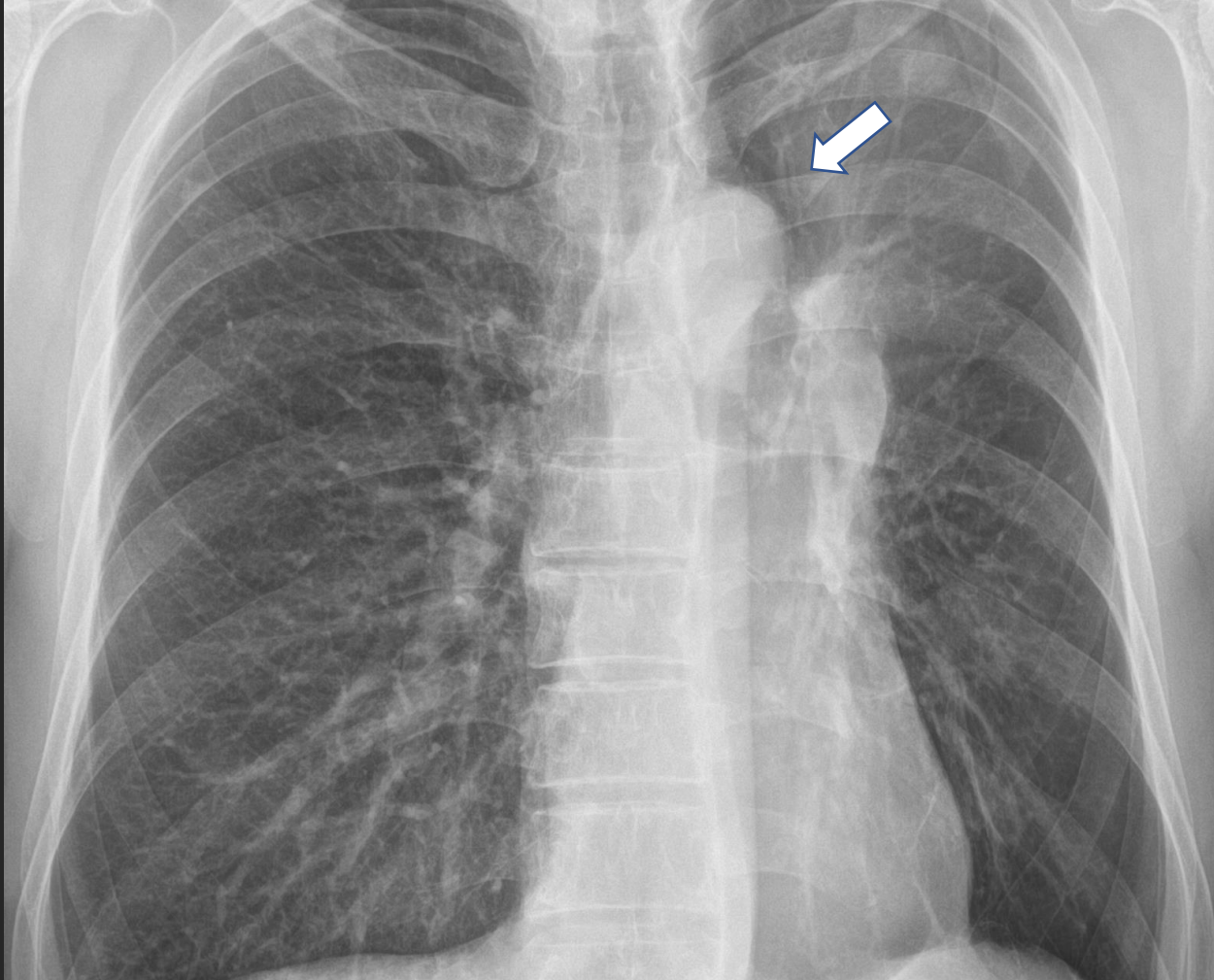
# Central type, Obstructive pneumonitis, inverted S



Let's Enjoy Dr Y's Chest Radiology



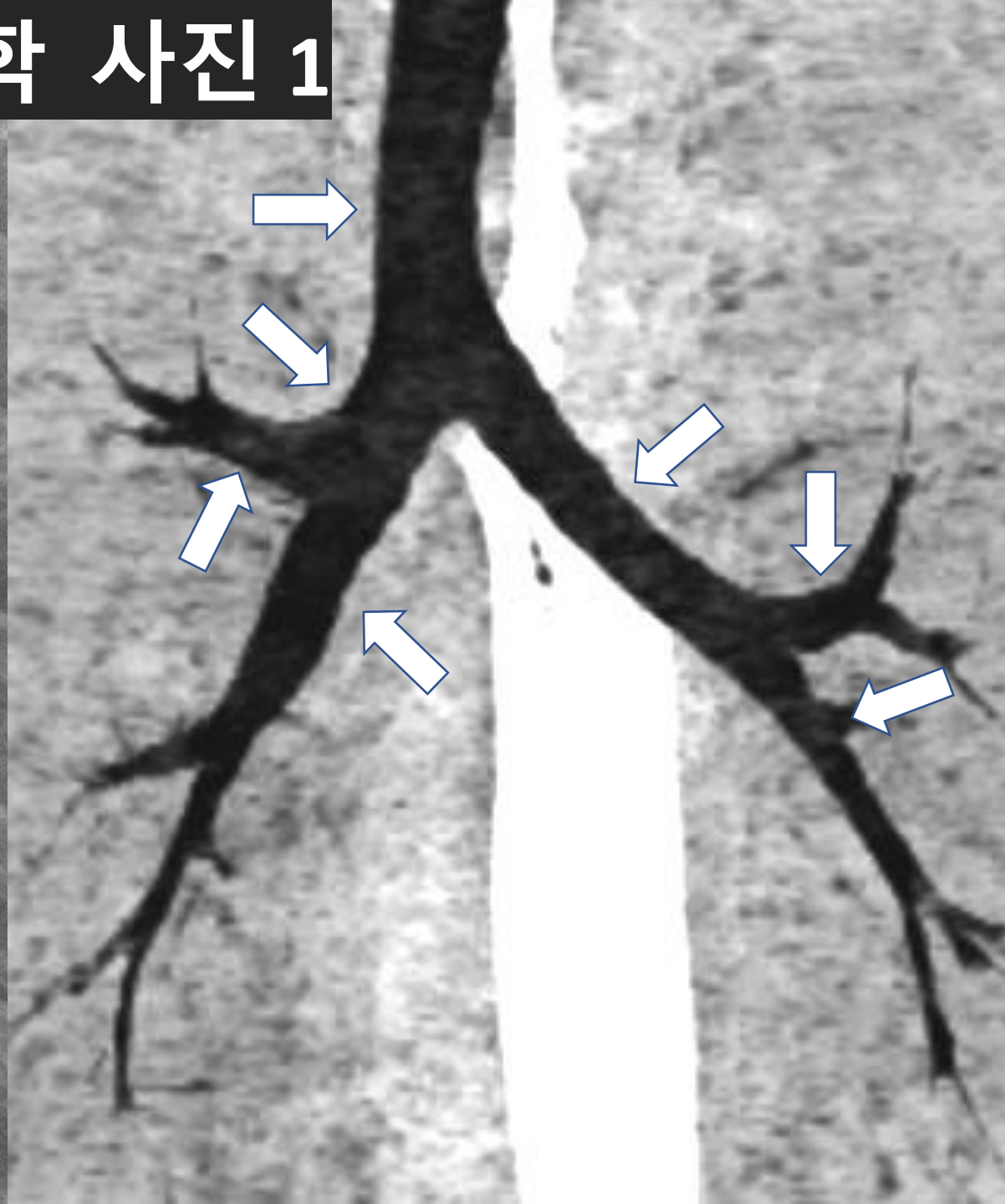
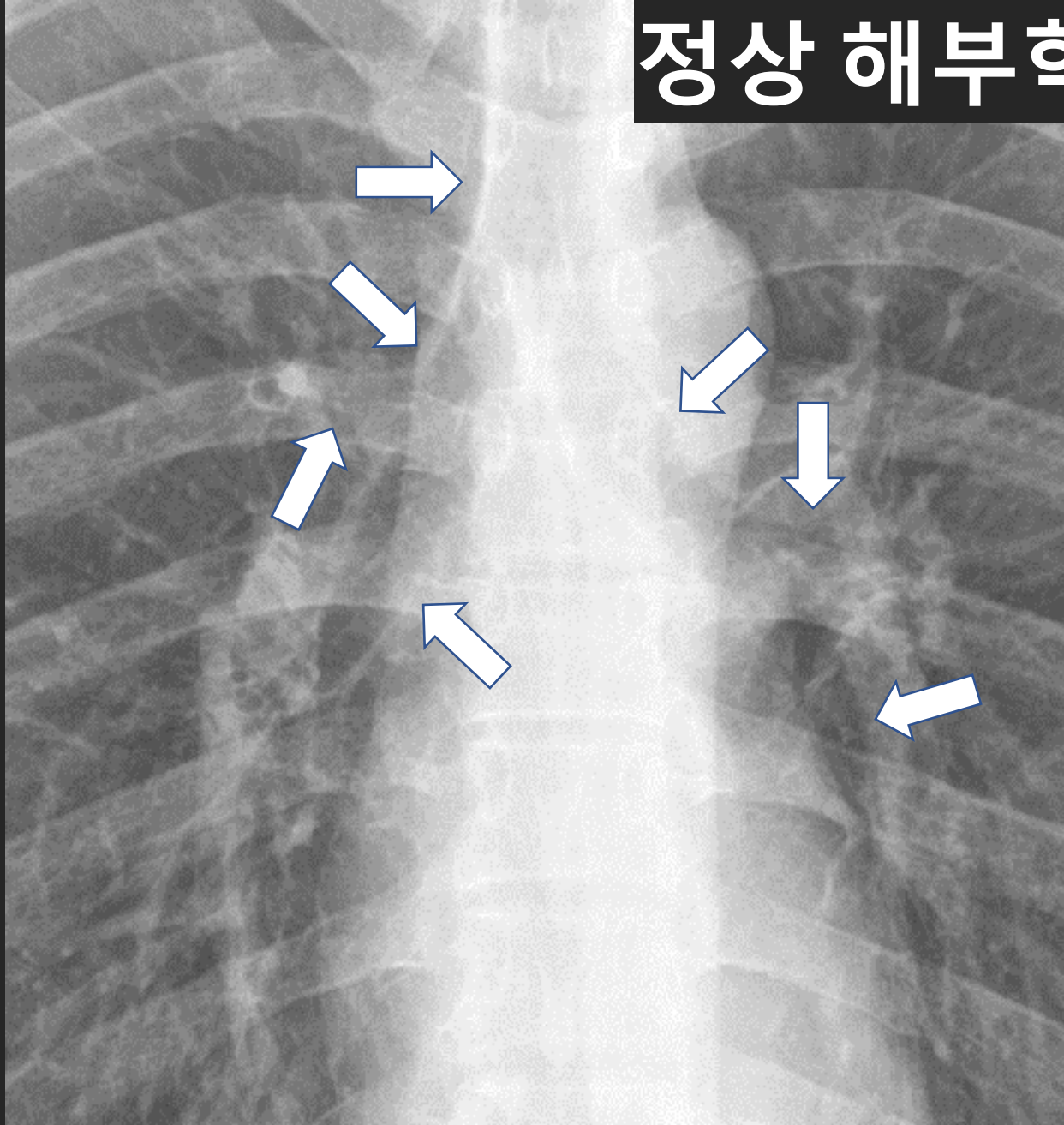
# Obst. Pn. Endobronchial mass , Golden' S



Obstructive pneumonia, Luft sichel

Let's Enjoy 닥터 와이 폐영상

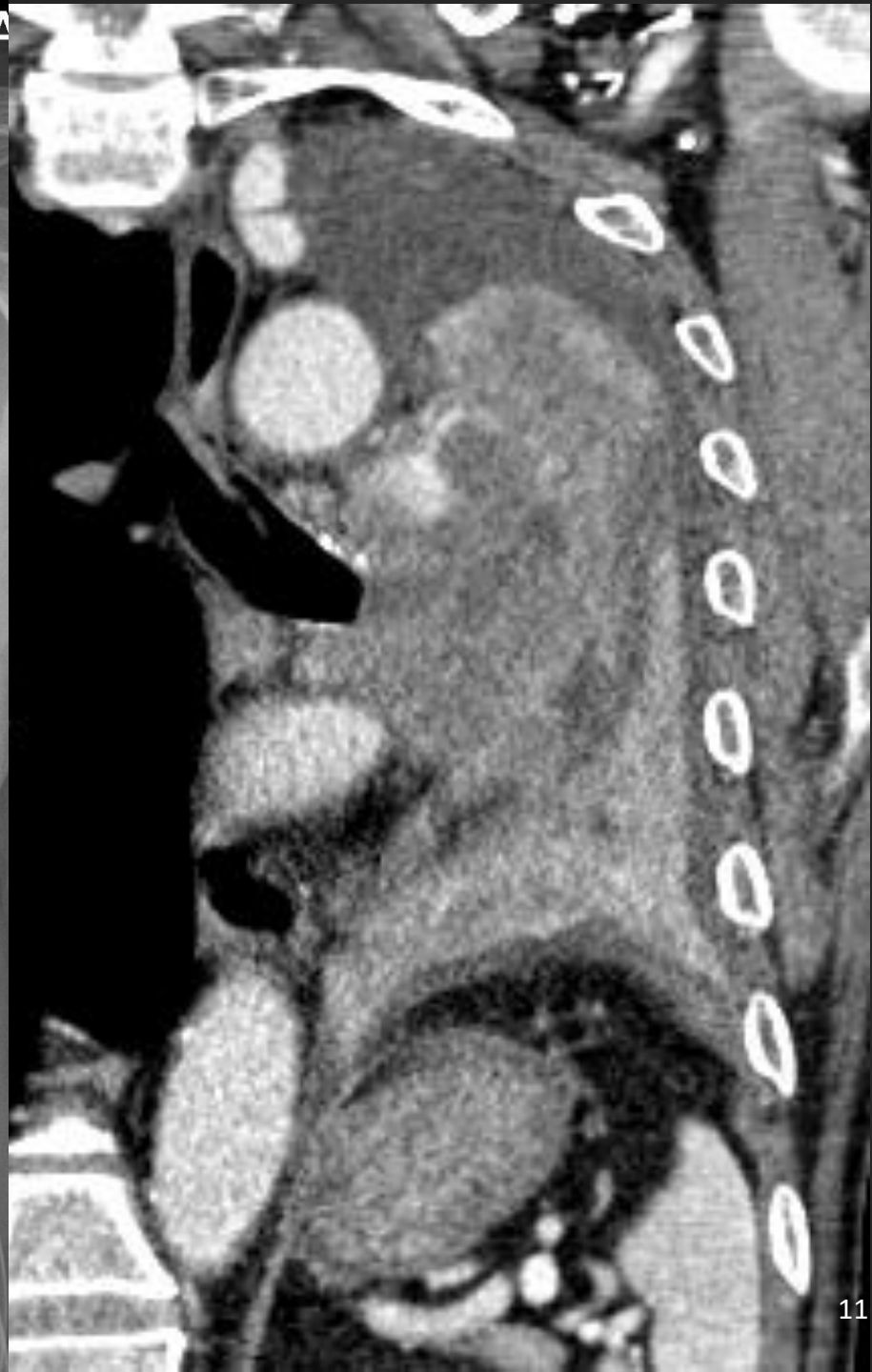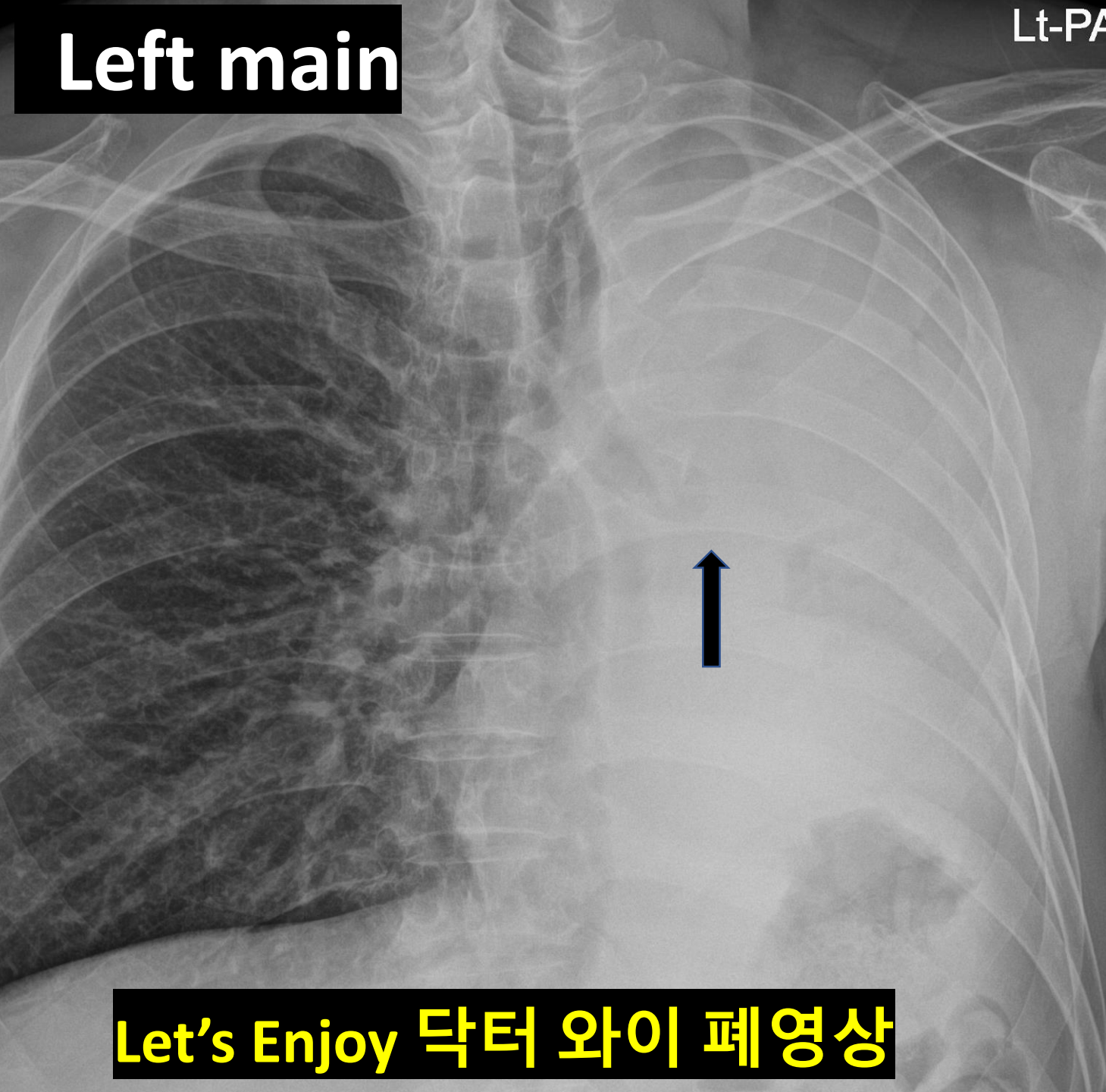
# 정상 해부학 사진 1



Let's Enjoy Dr Y's Chest Radiology

**Left main**

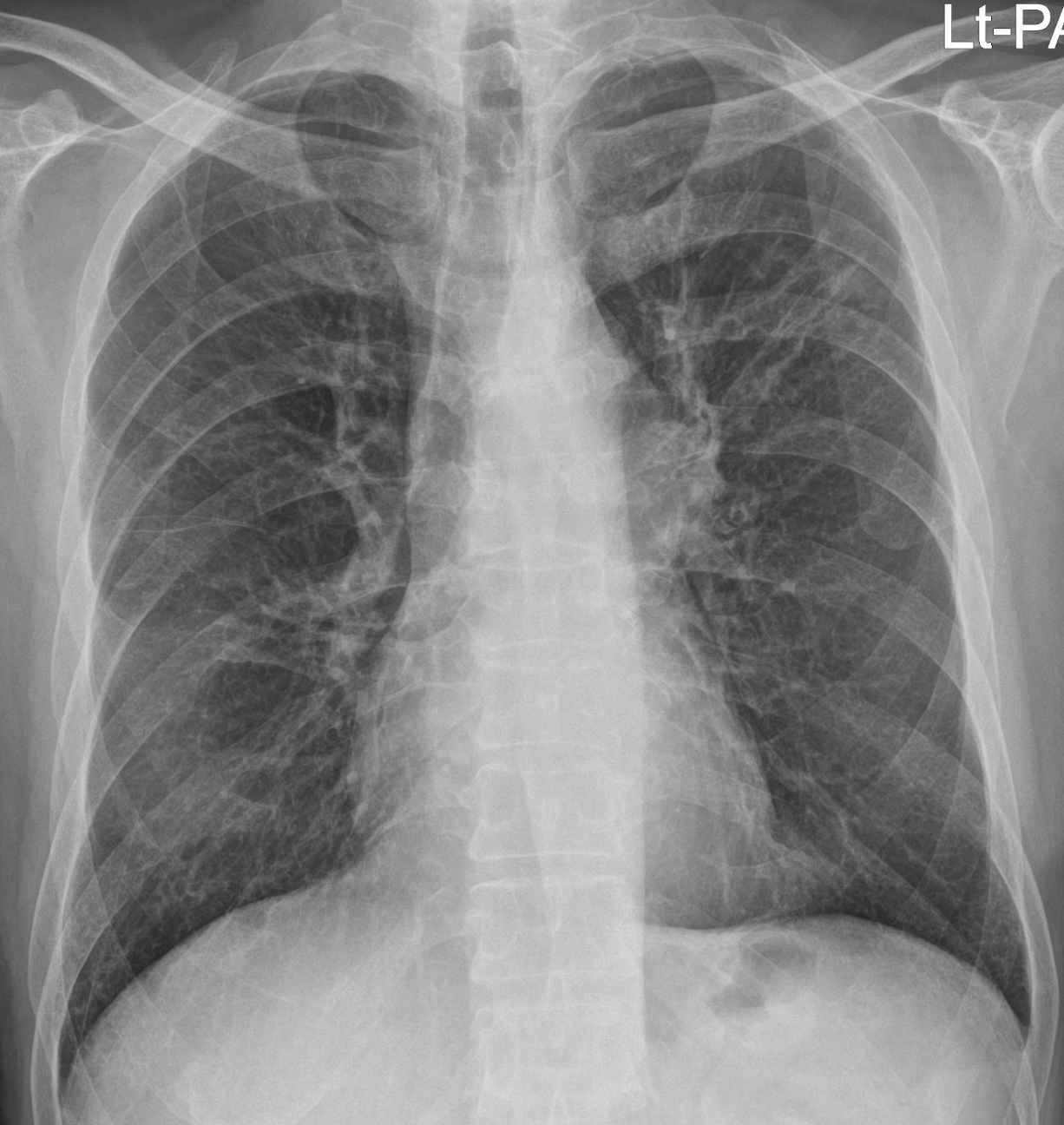
Lt-PA



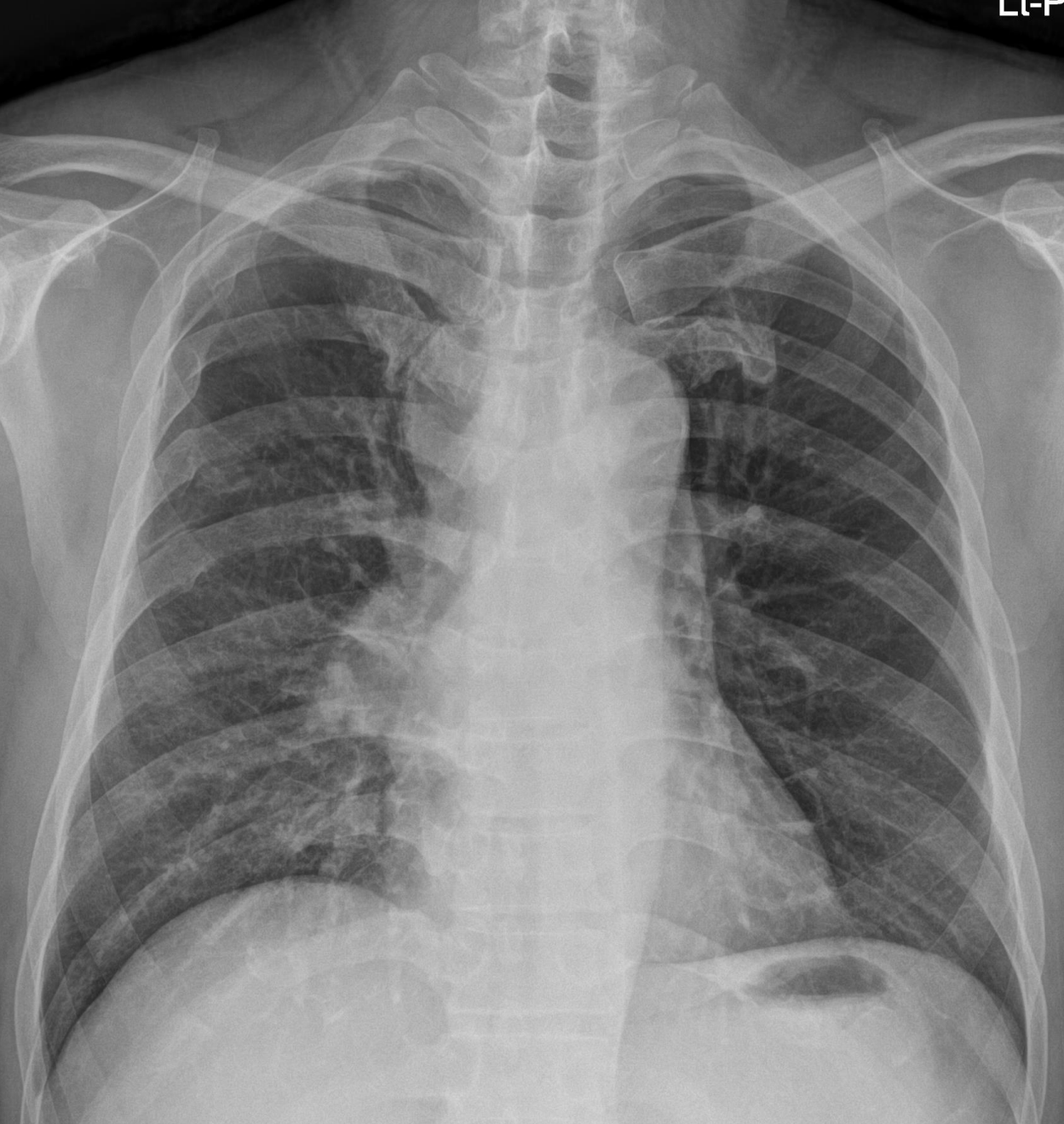
**Let's Enjoy 닥터 와이 폐영상**

Lt-PA

# Mediastinal mass

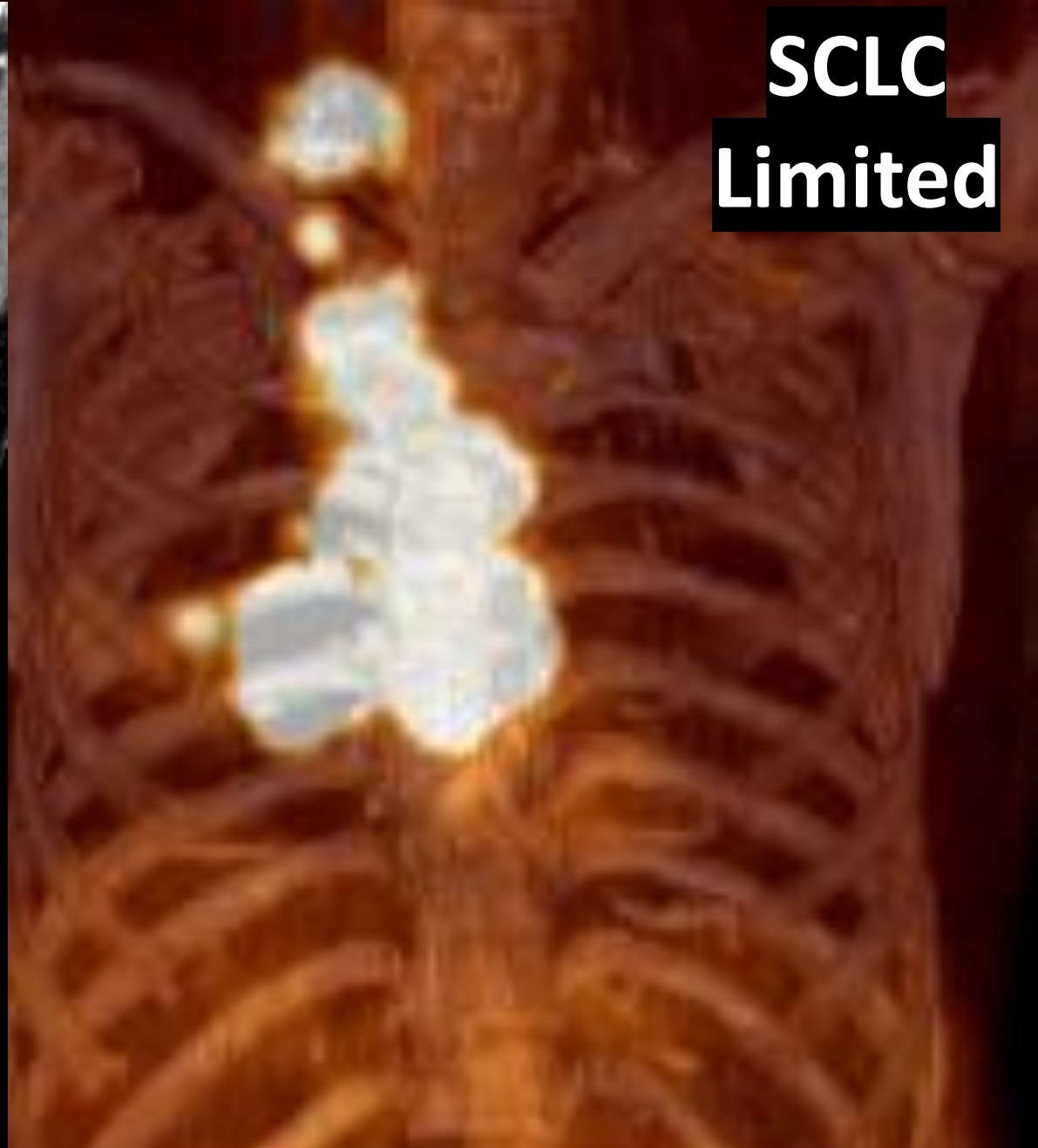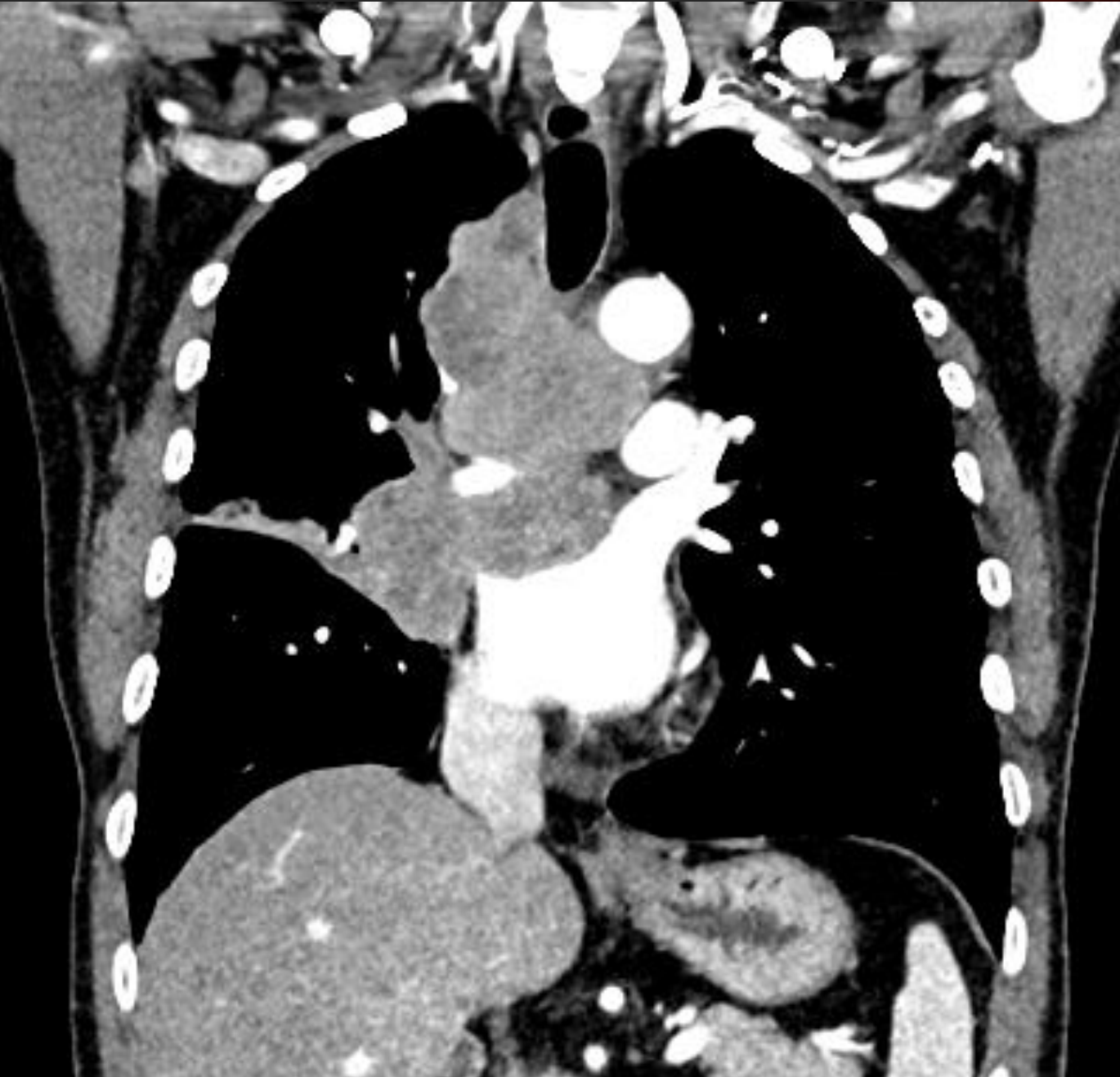


Let's Enjoy 닥터 와이 폐영상



어깨는 하나다

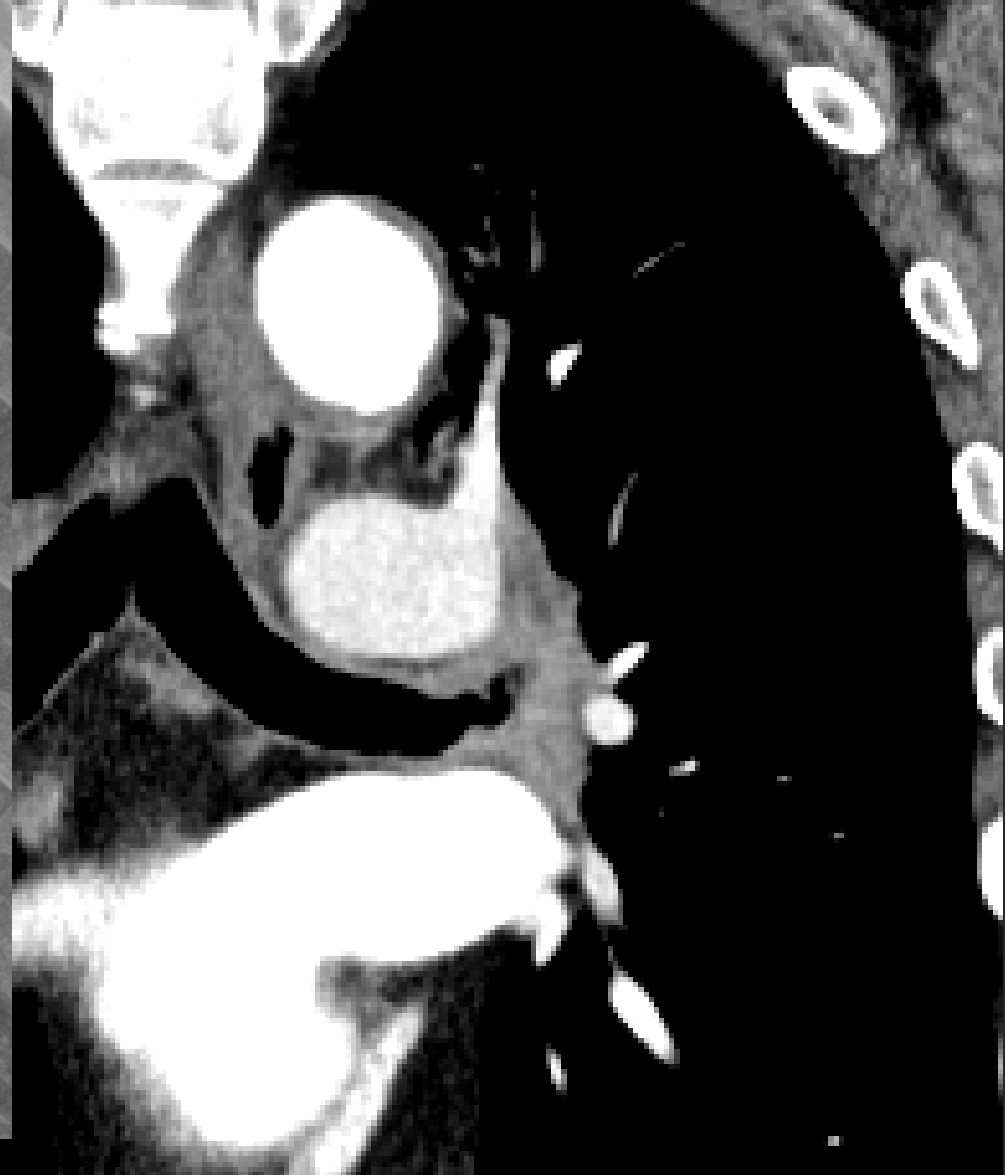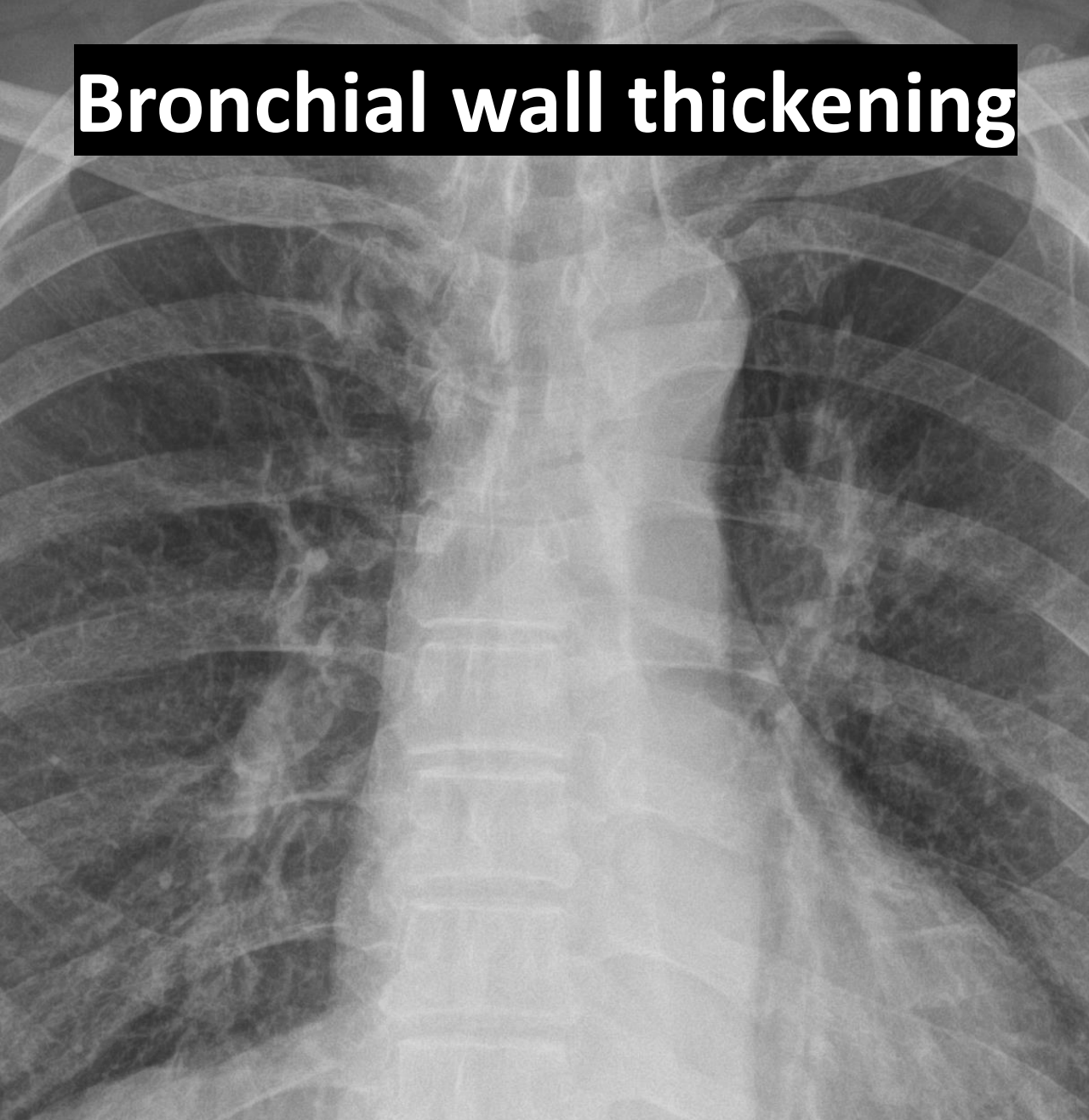**Let's Enjoy the Chest Radiograph with Dr Y Chest Radiology**



**SCLC  
Limited**

**Let's Enjoy the Chest Radiograph with Dr Y Chest Radiology**

# Bronchial wall thickening



Let's Enjoy Dr Y's Chest Radiology

**A. Central type**

**B. Peripheral type**

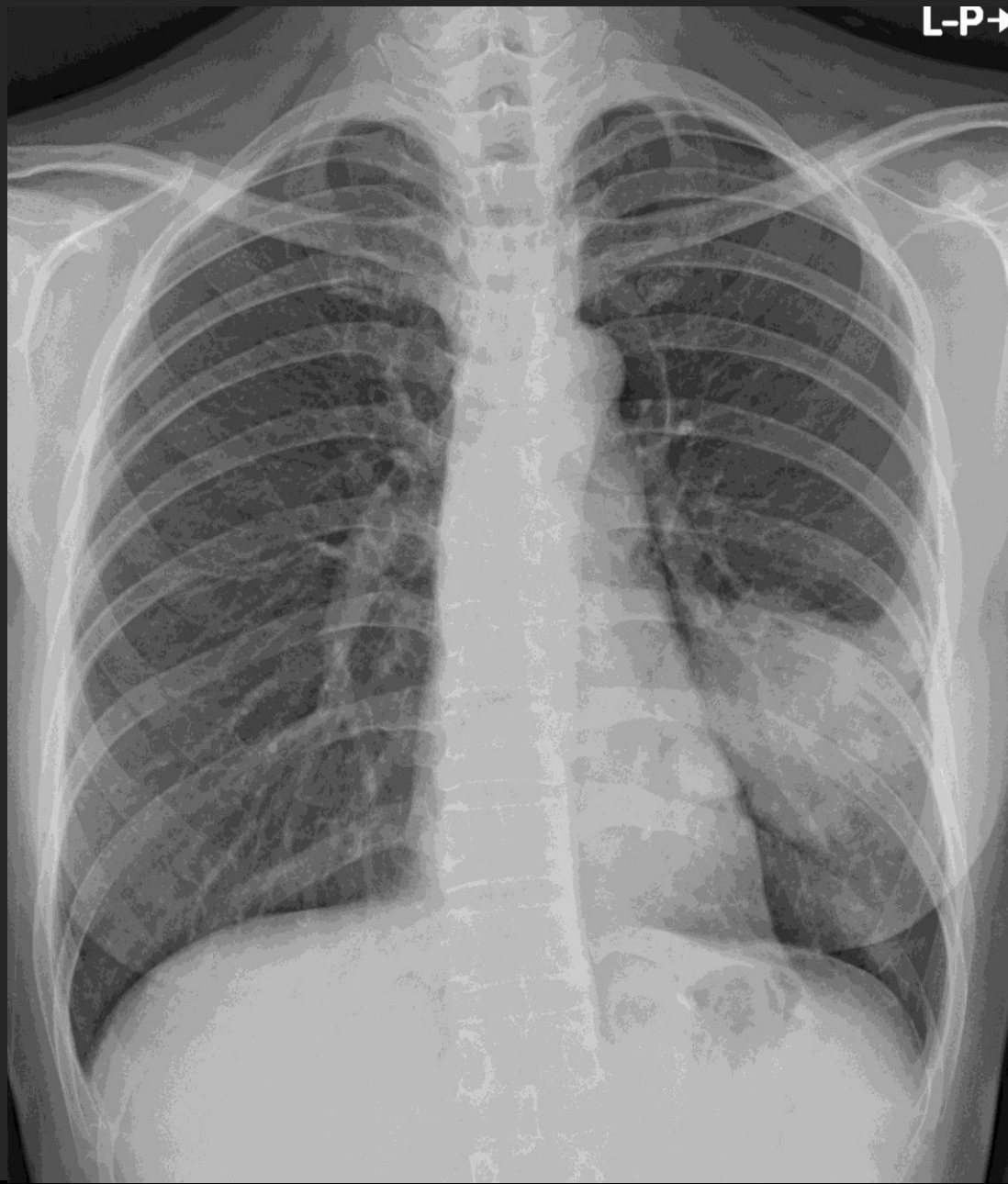**C. “Missed” lung cancer**

**D. New or Grow :**

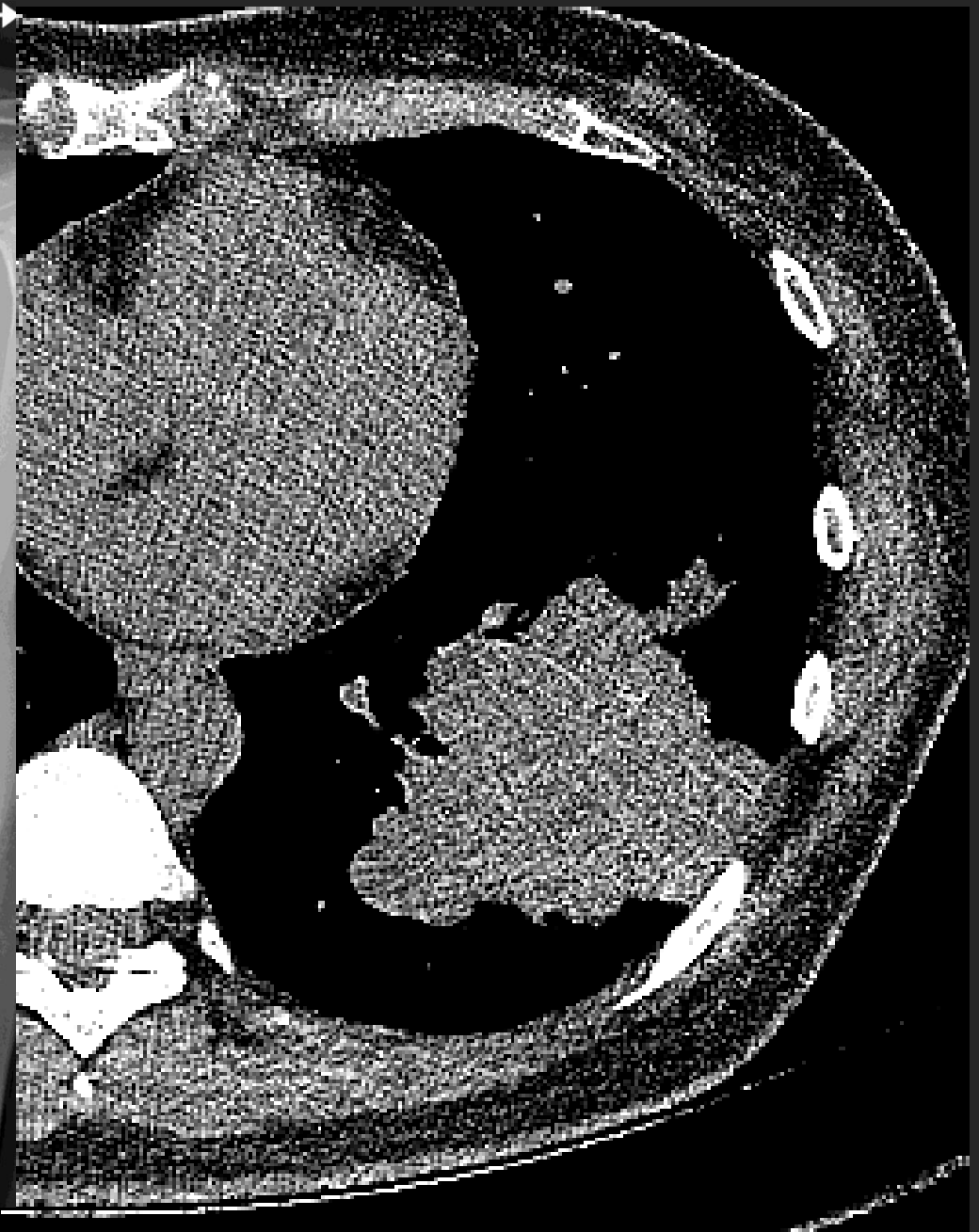

## B. 변두리 폐암, peripheral type

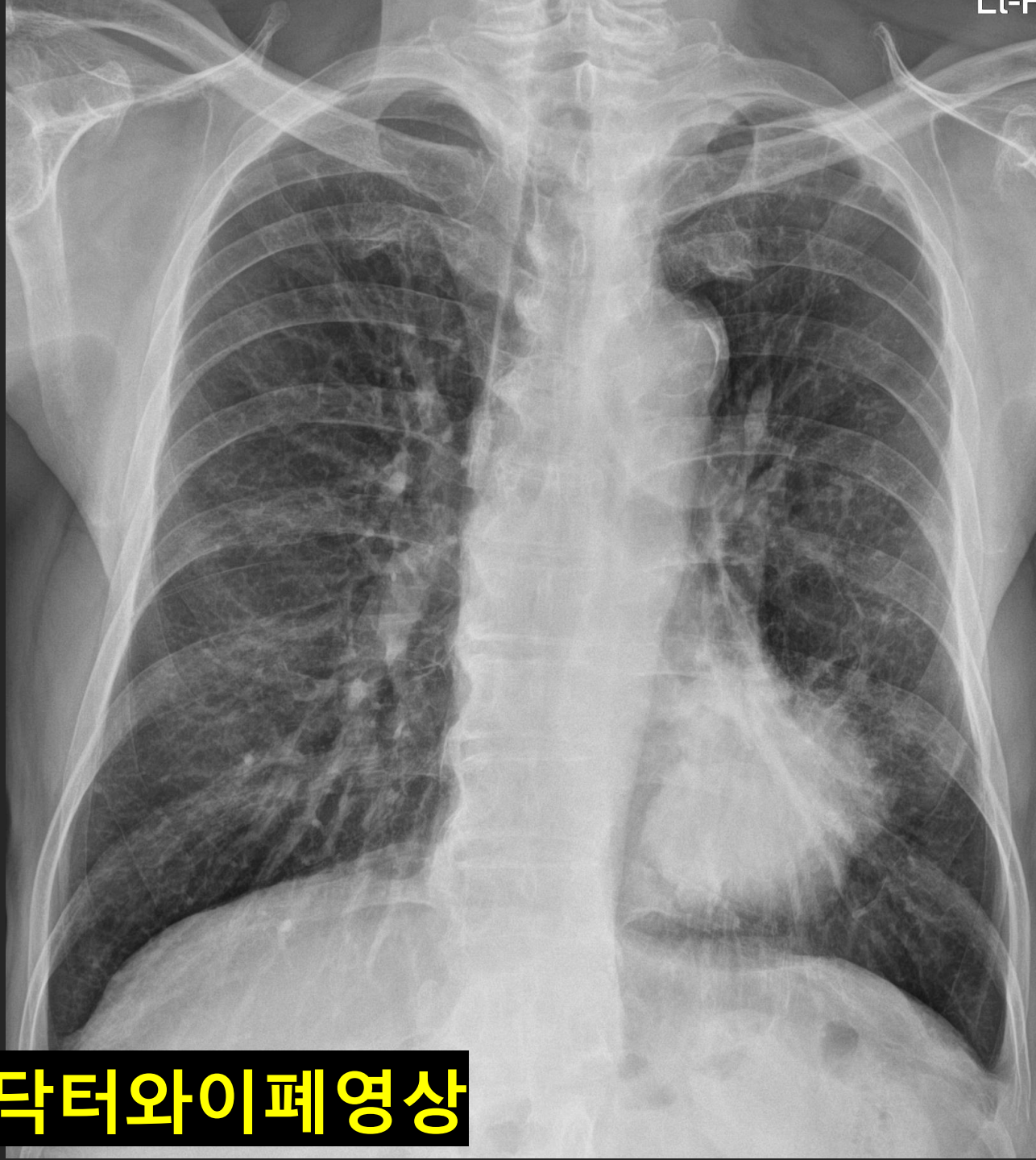- a. Mass;  $> 3$  cm
- b. Nodule (SPN) ;  $\leq 3$  cm
- c. Ground Glass Nodule (GGN)
- d. Consolidation



L-P →



**Let's Enjoy Dr Y's Chest Radiology**



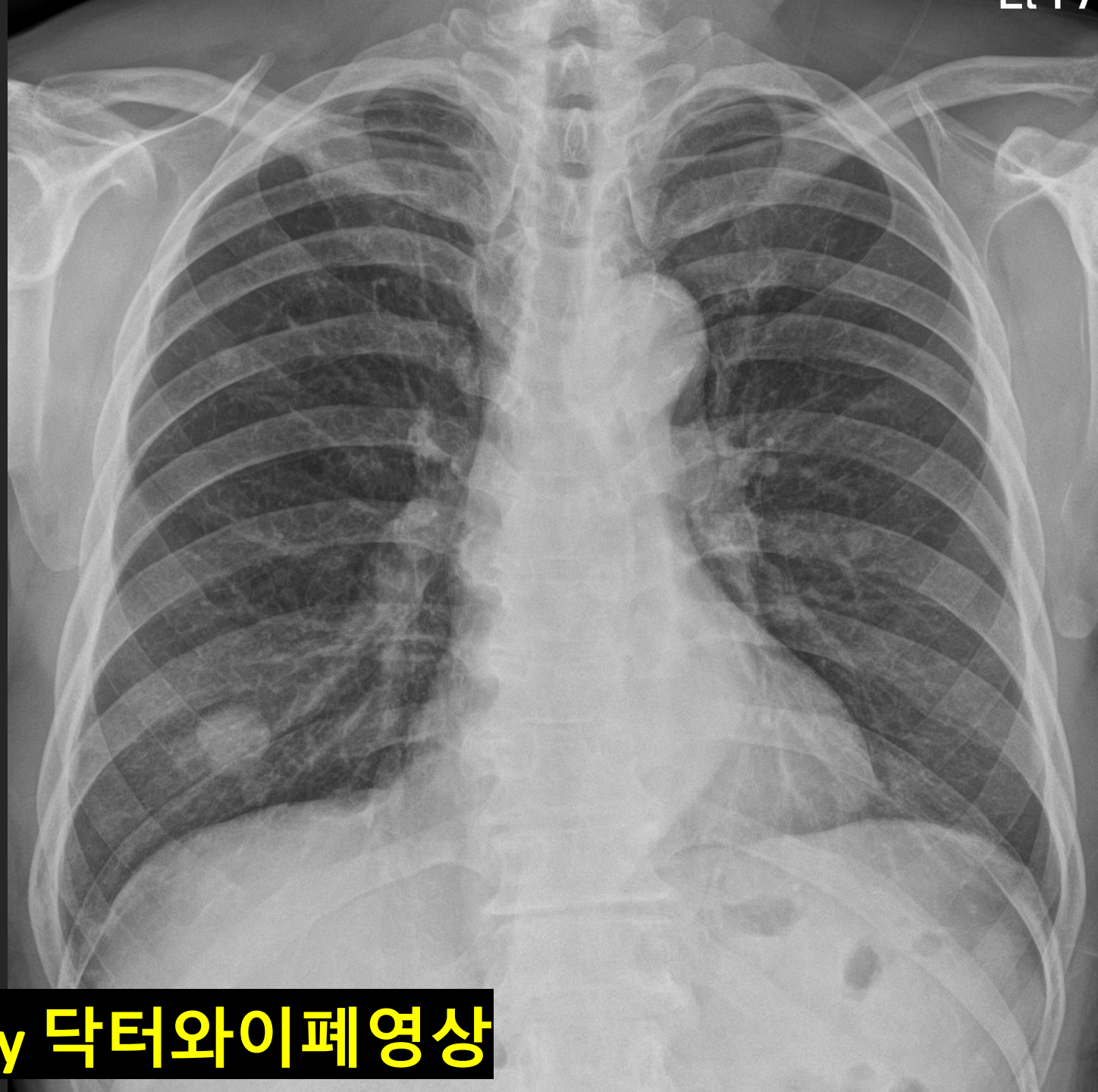
**Let's Enjoy 닥터와이폐영상**



이주일

담배 맛있습니까? 그거 독약입니다

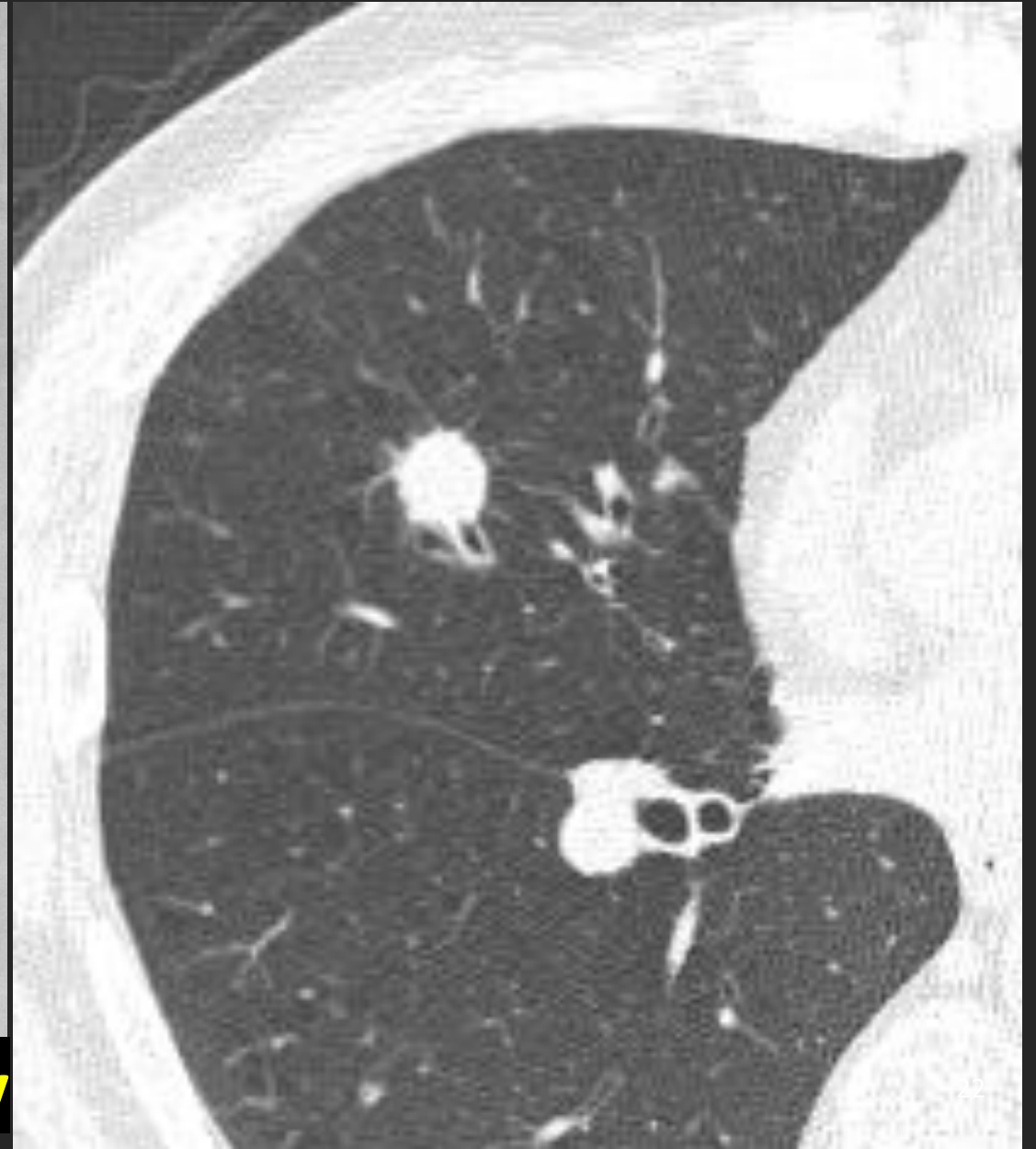
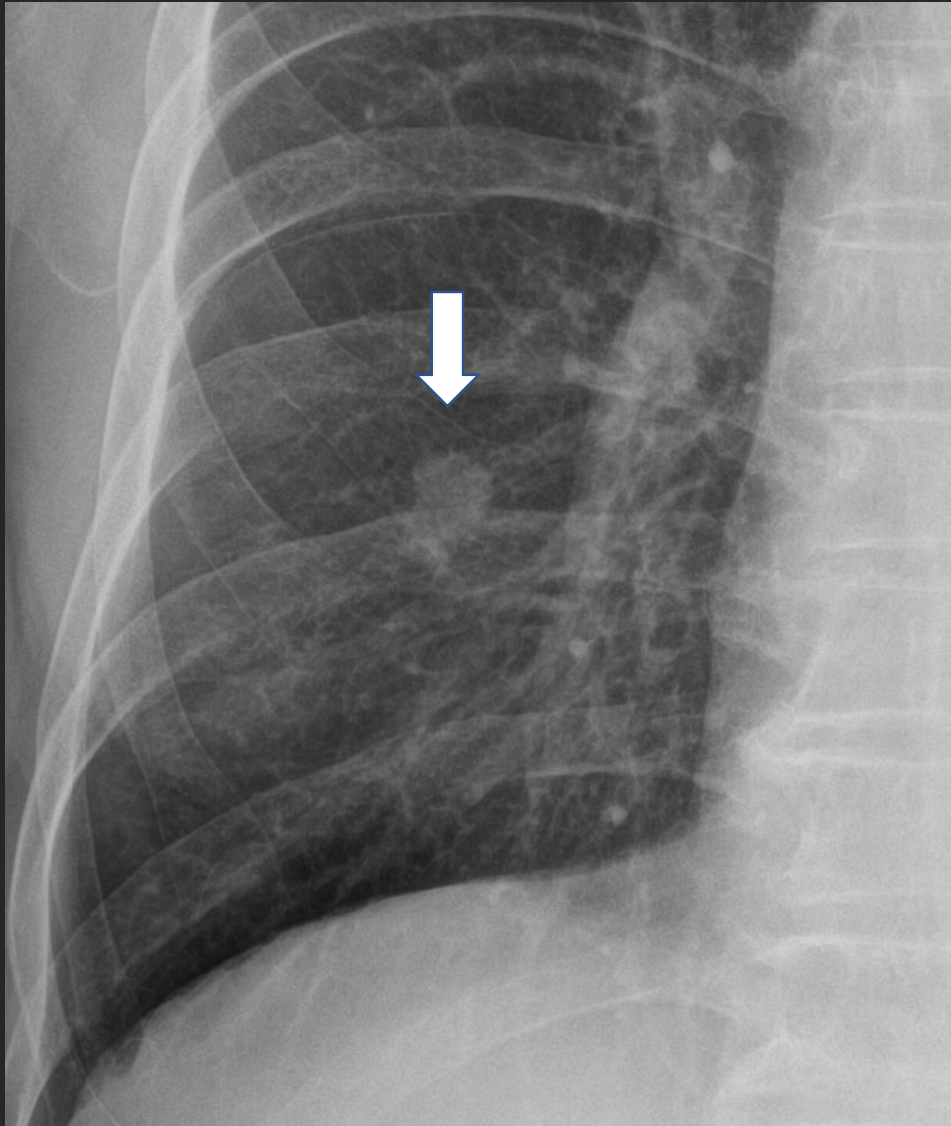
Let's Enjoy the Chest Radiograph with Dr Y Chest Radiology



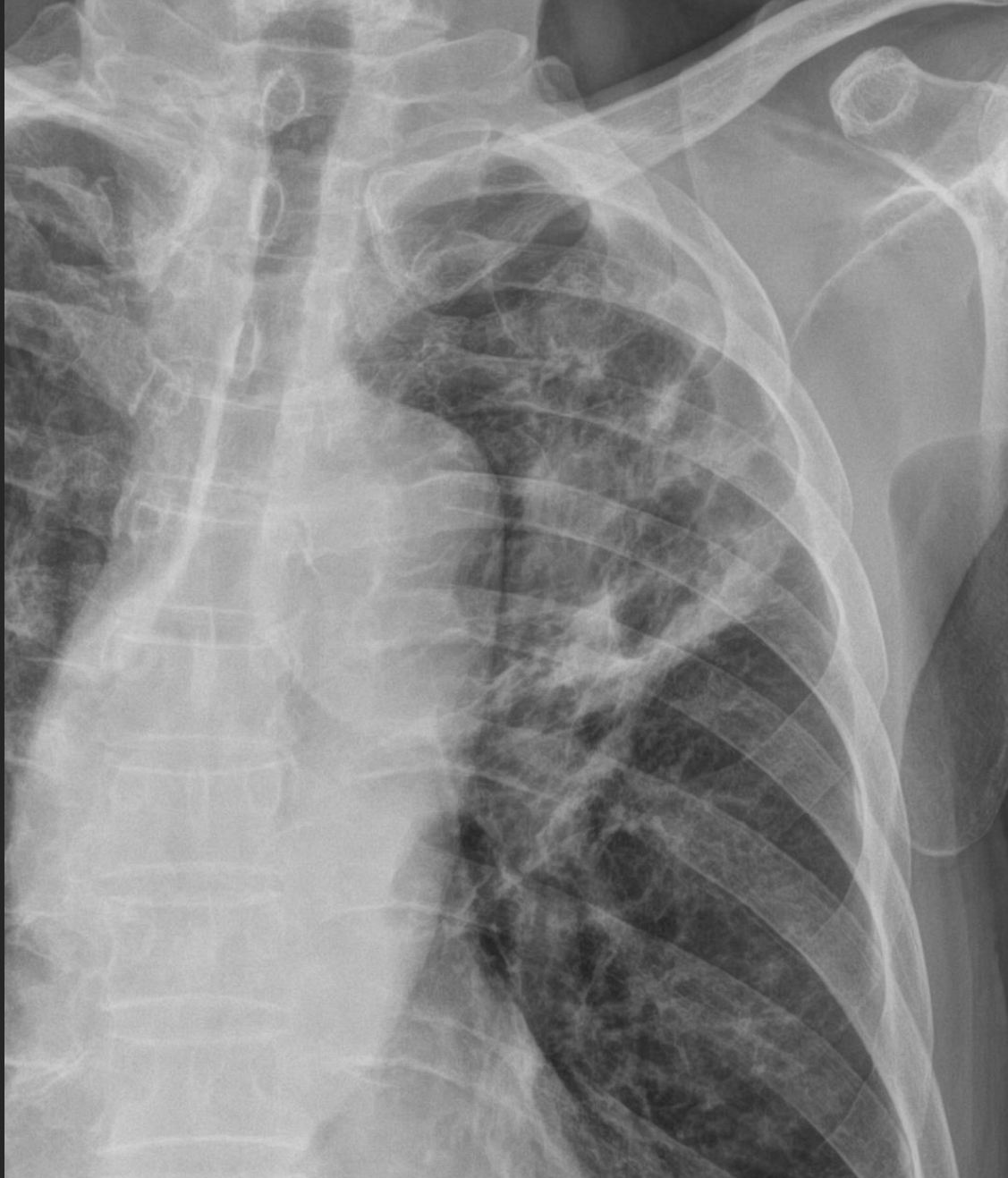
**Nodule**  
**SPN**  
**Coin**

**Let's Enjoy 닥터와이폐영상**

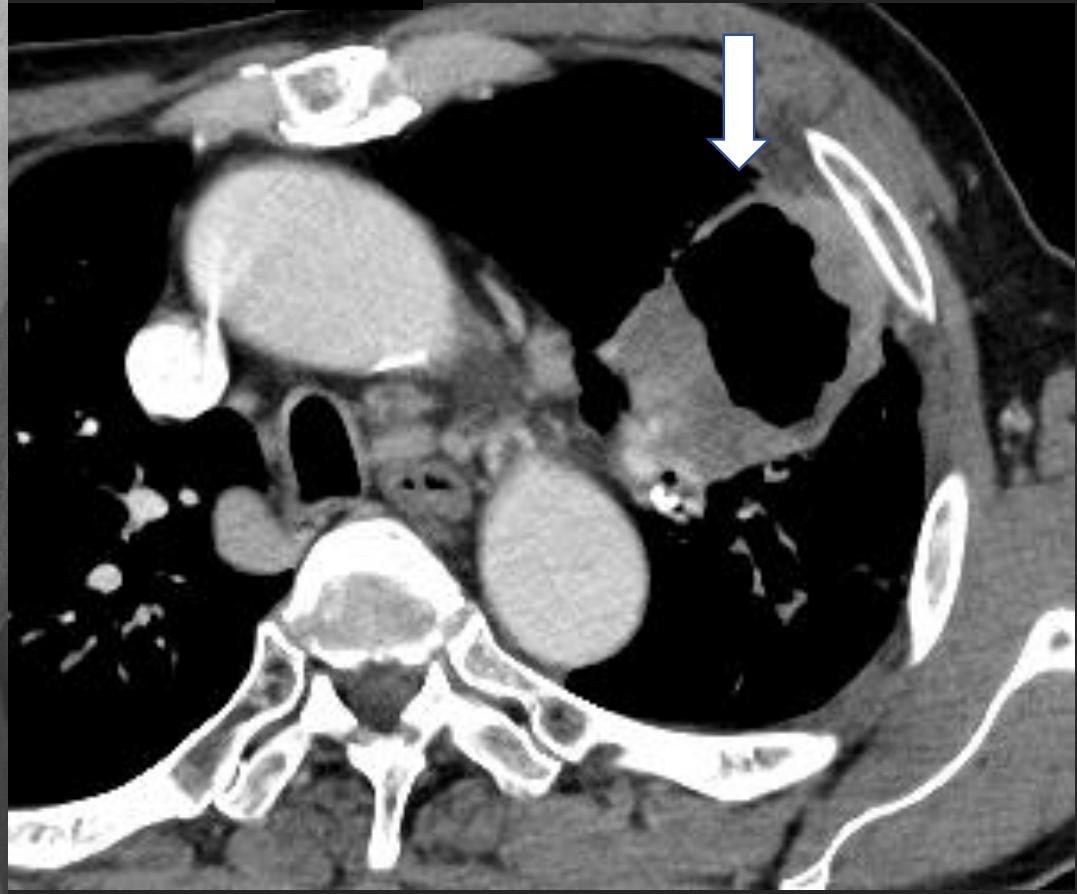
# Nodule, adenocarcinoma; “spiculation”



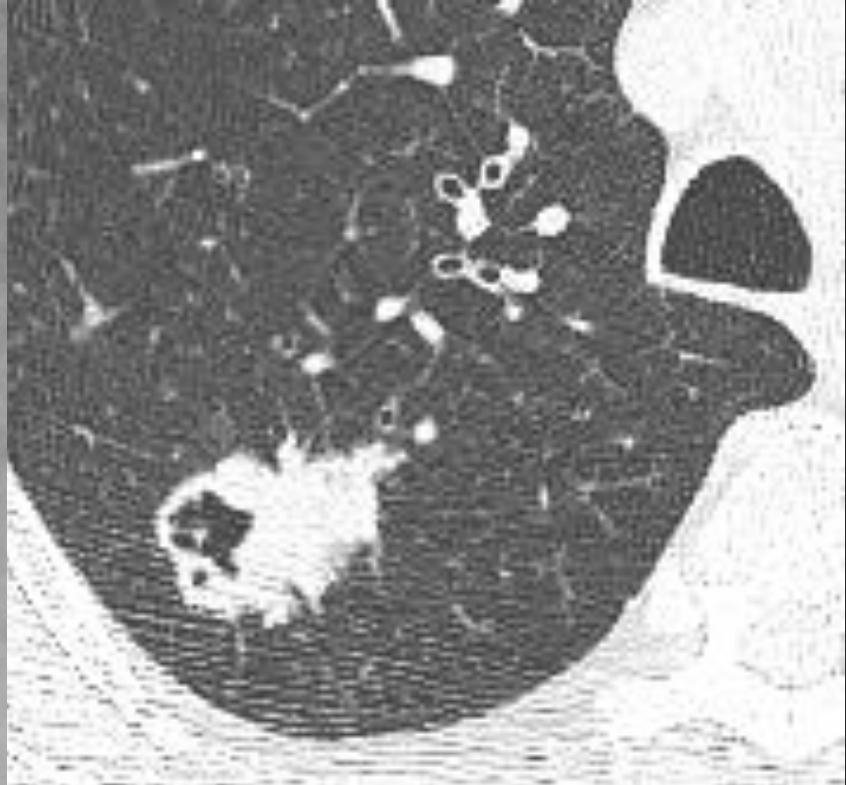
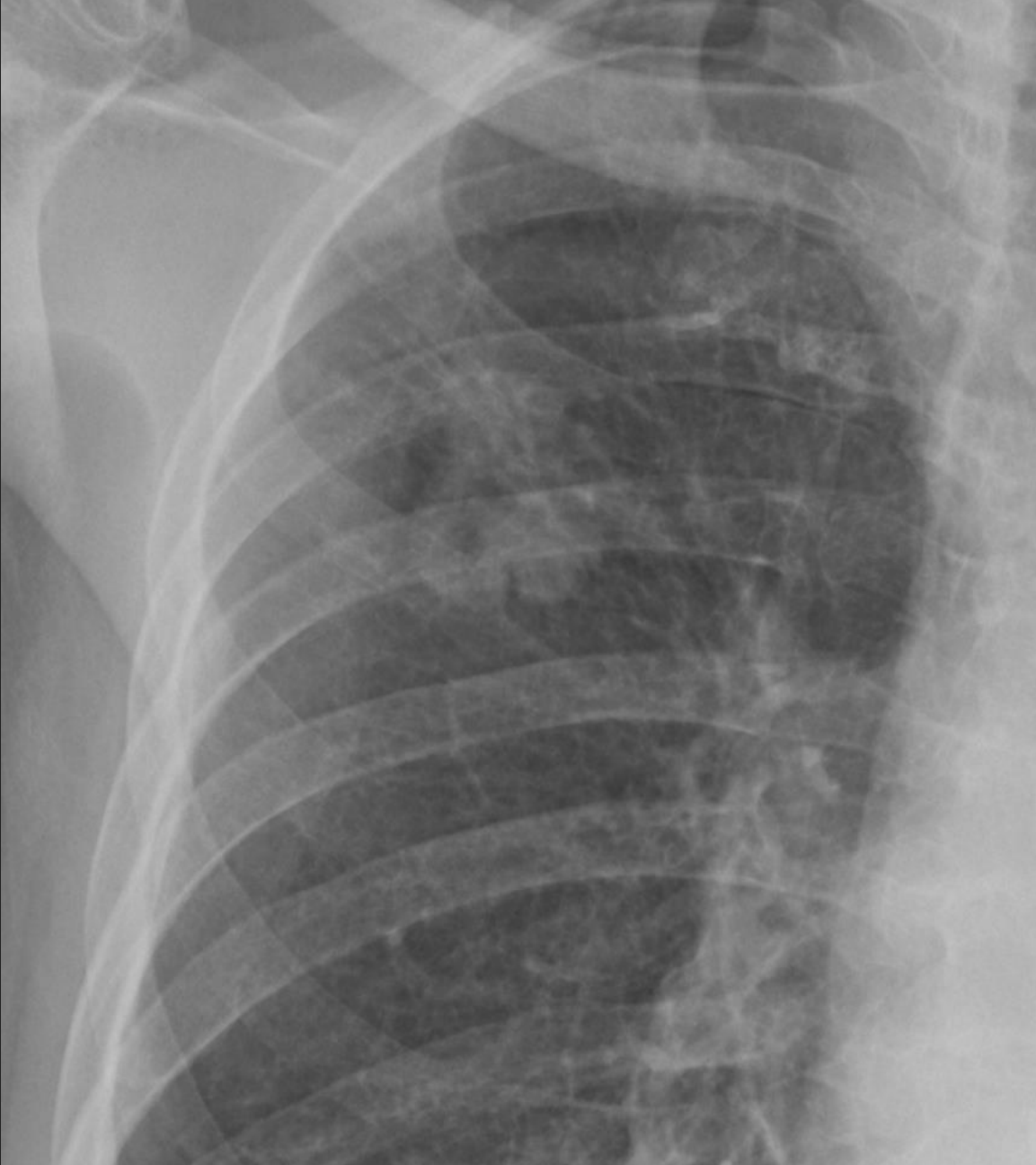
Let's Enjoy Dr Y's Chest Radiology



**Cavity  
SCC**

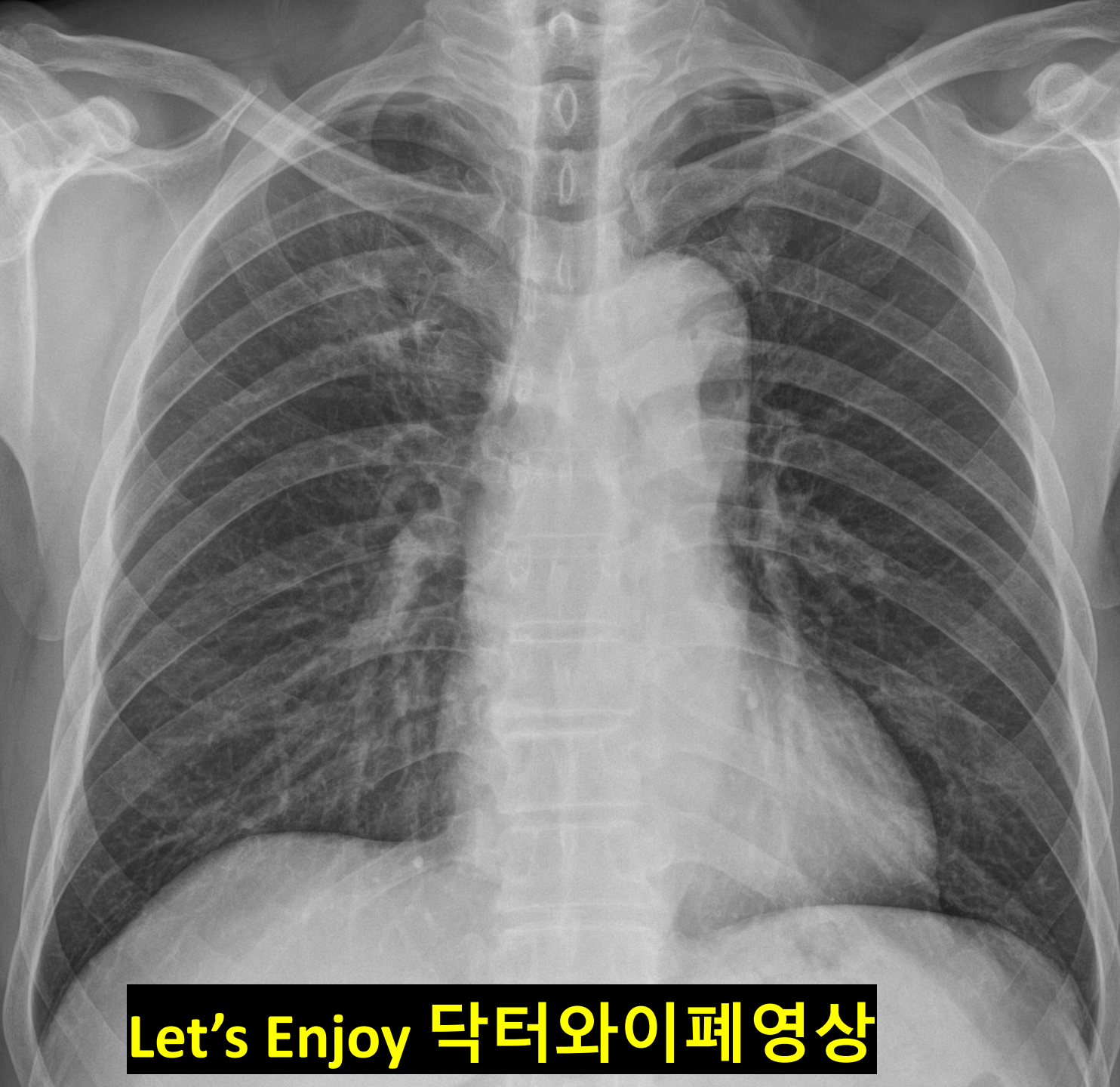


**Let's Enjoy Dr Y's Chest Radiology**



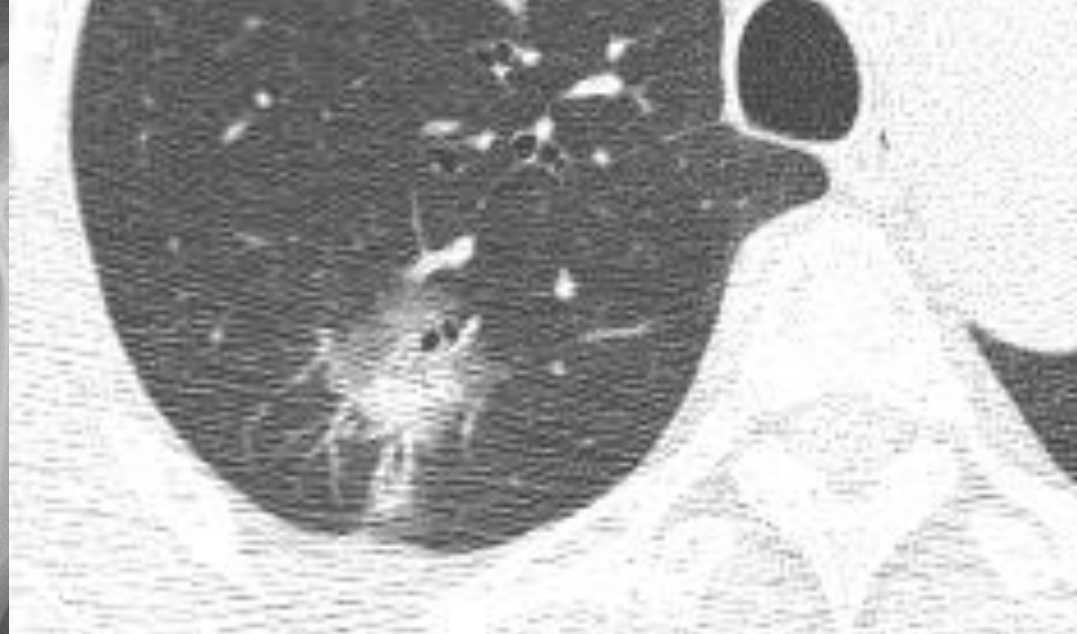
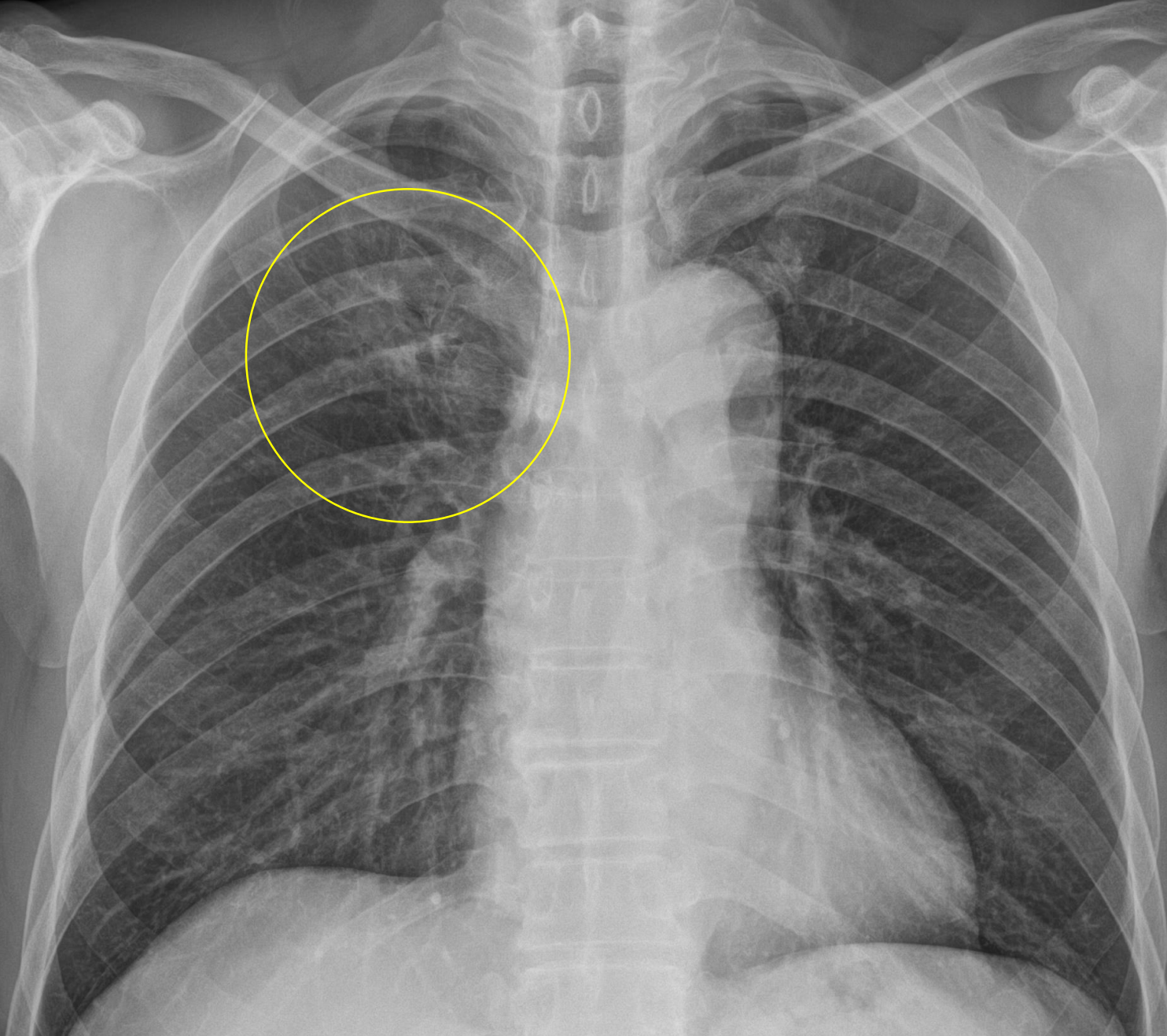
**Let's Enjoy 닥터와이폐영상**



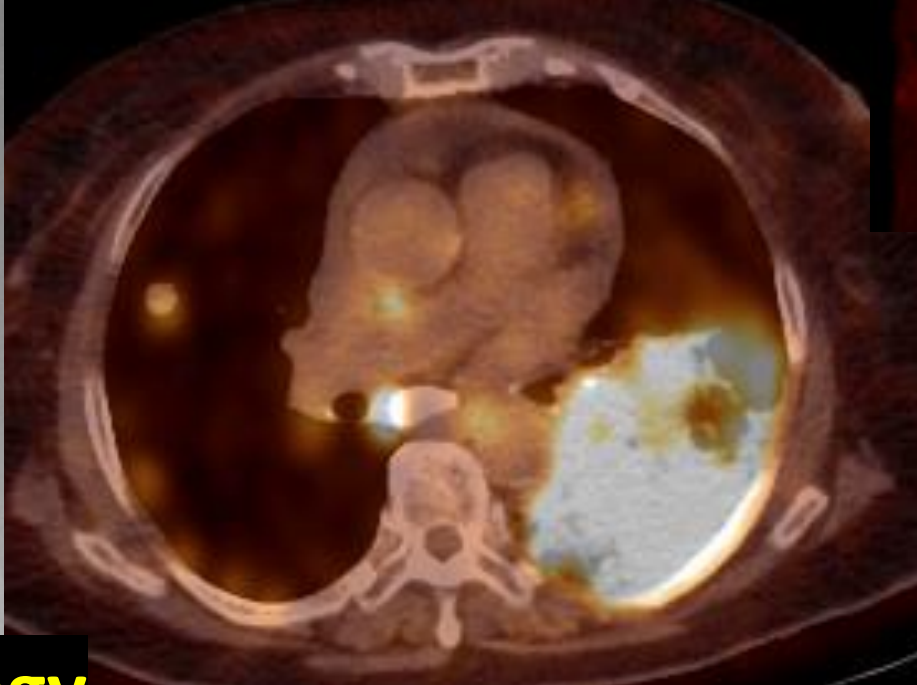
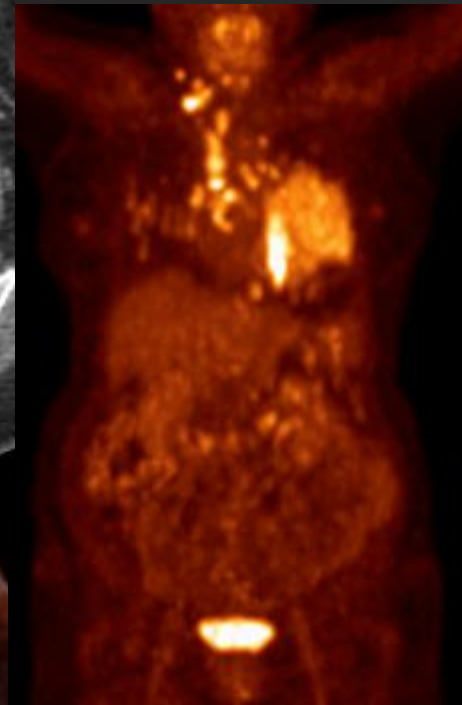
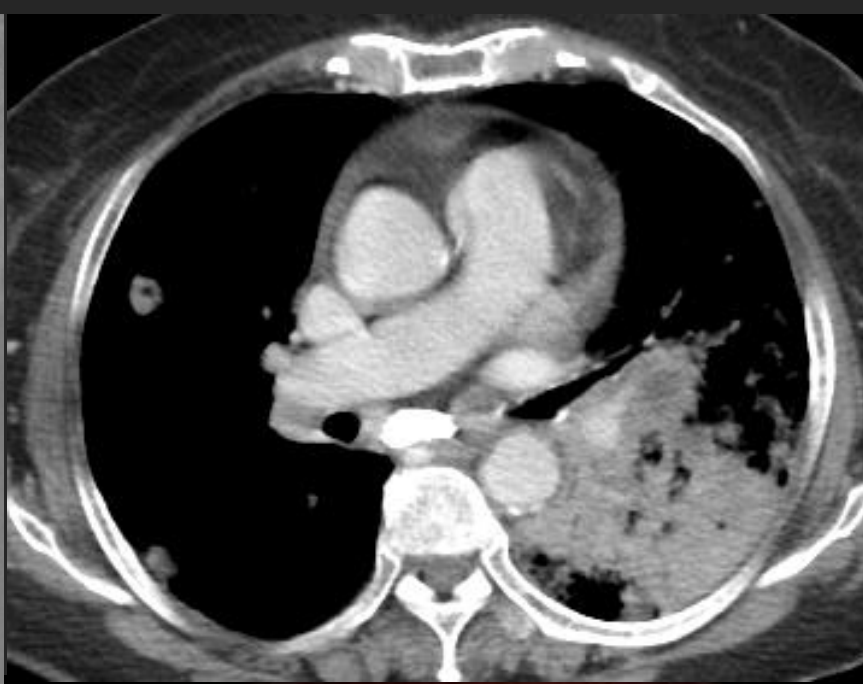
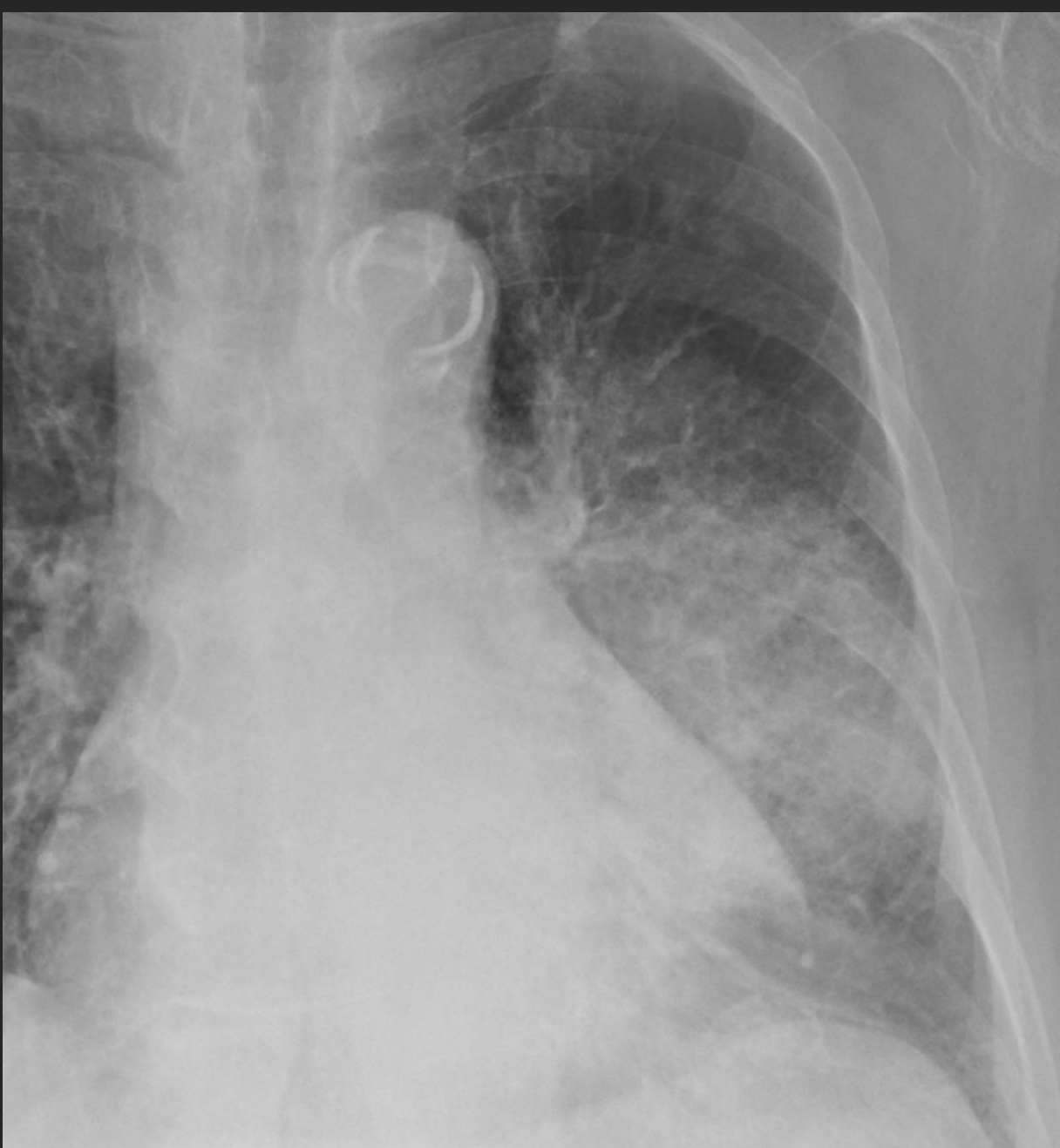
# Peripheral type Ground Glass Nodule

Let's Enjoy 닥터와이폐영상

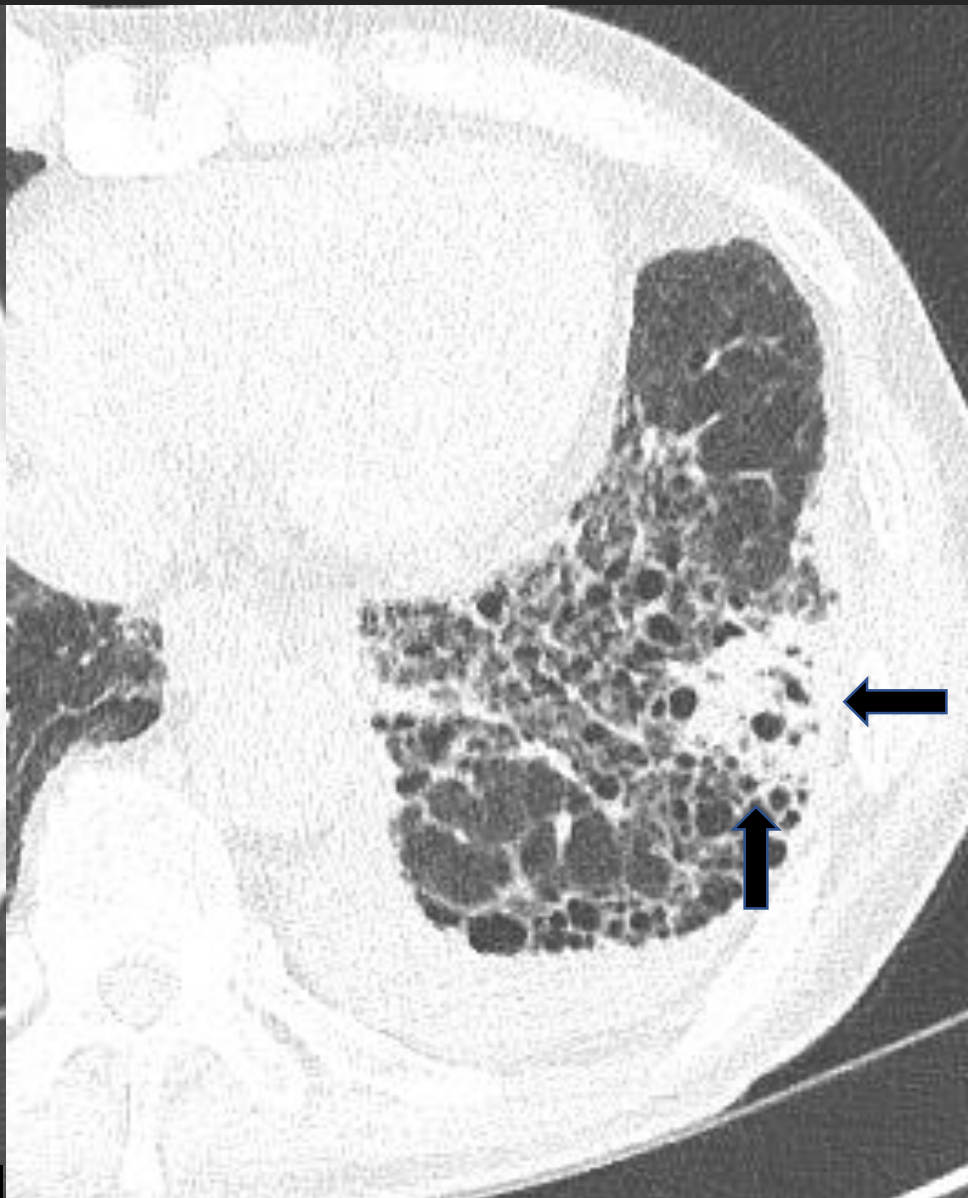
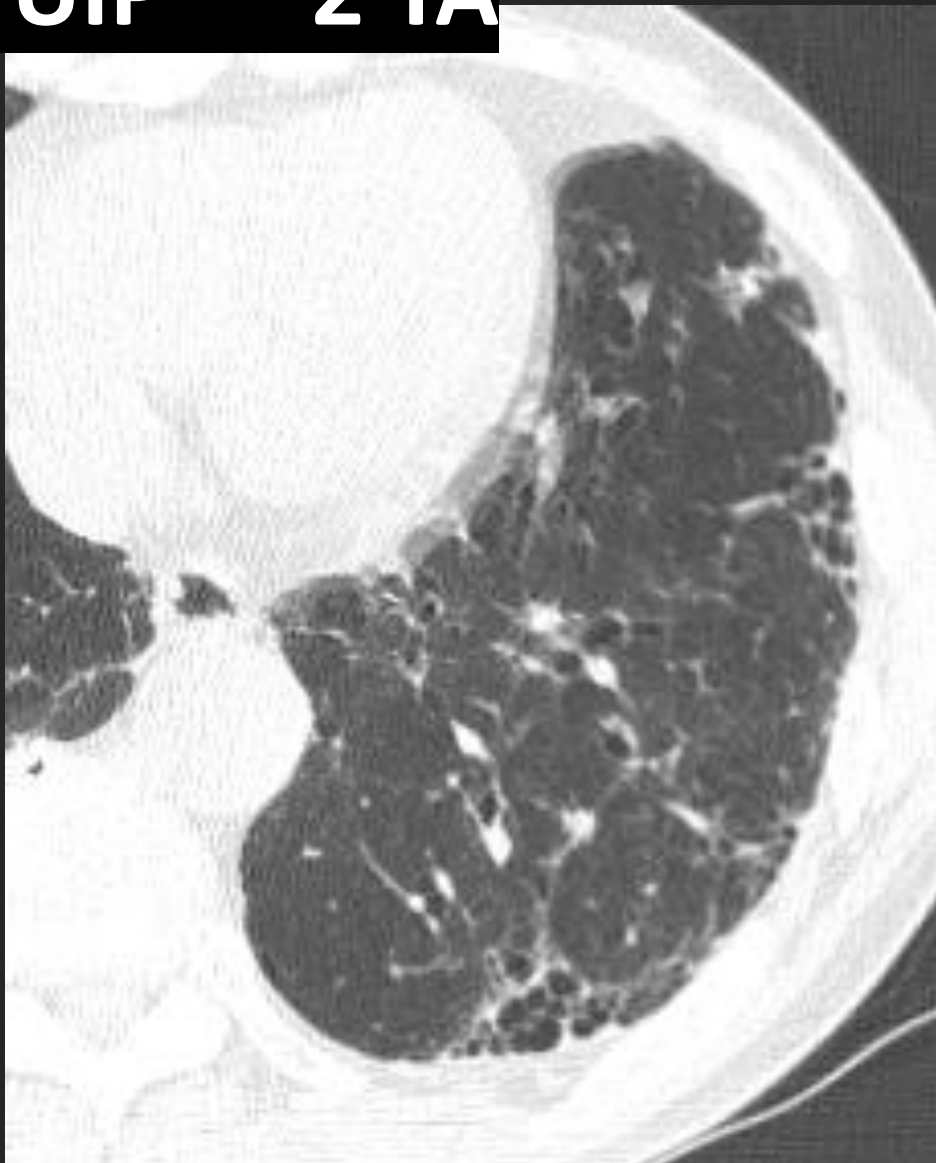


**Let's Enjoy the Chest Radiograph with Dr Y Chest Radiology**



**Let's Enjoy Dr Y's Chest Radiology**

**IPF/UIP 2 YA**

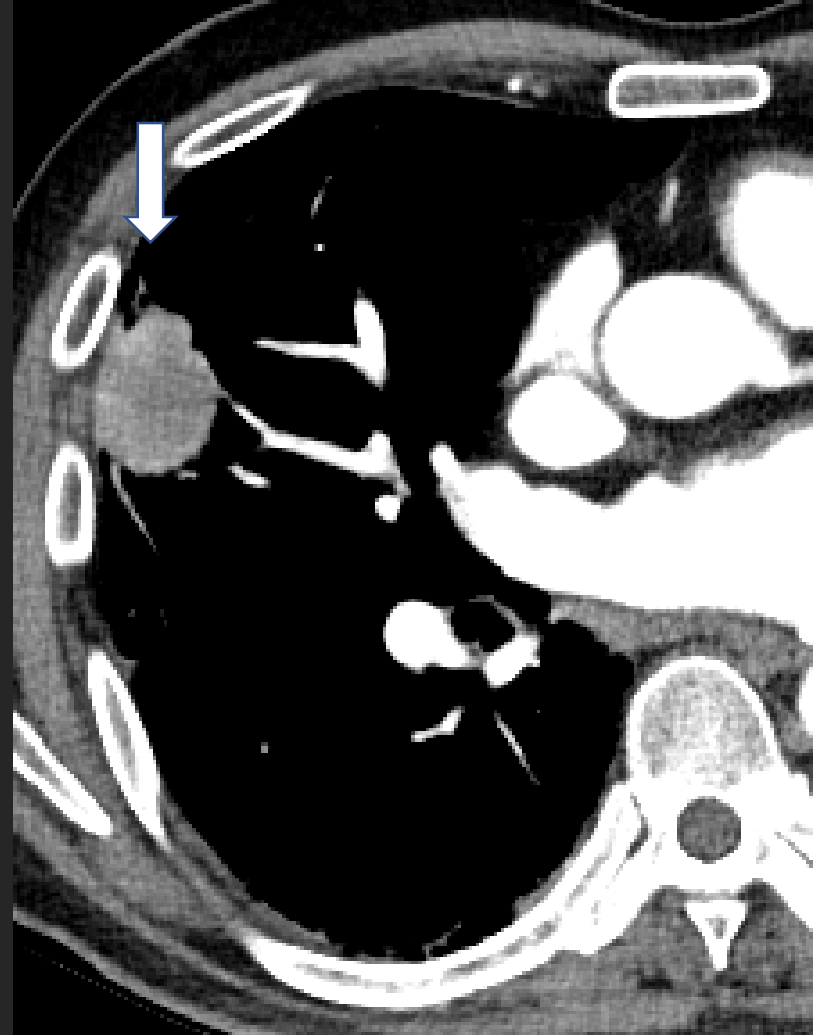
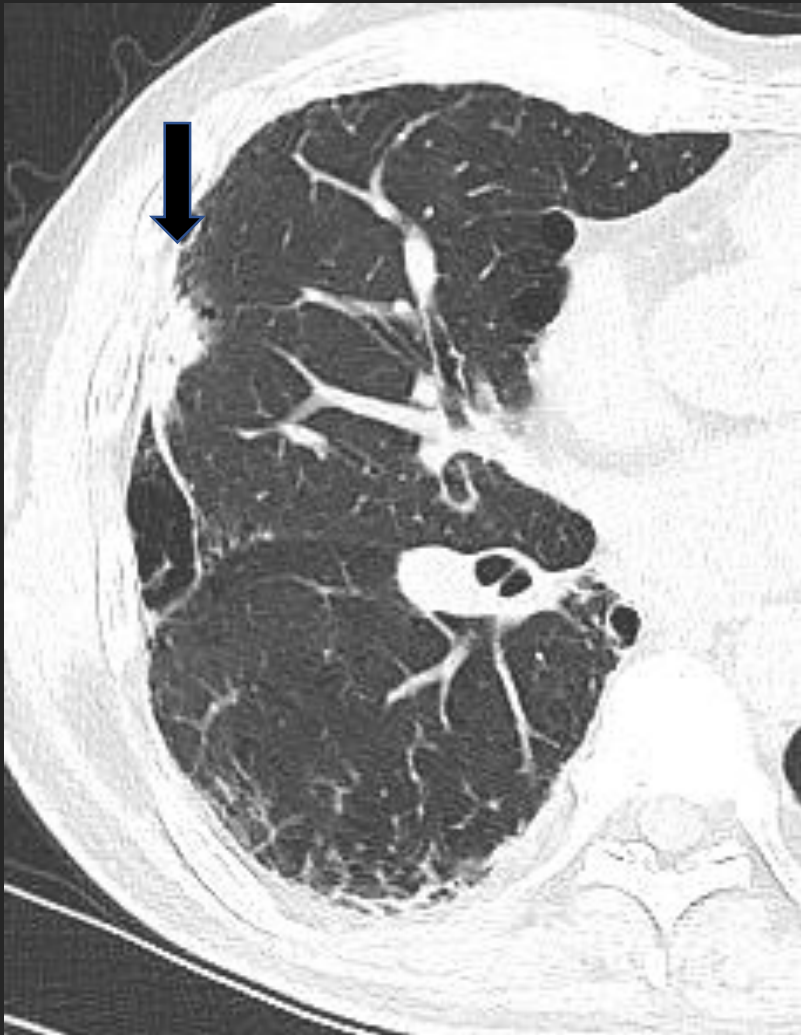
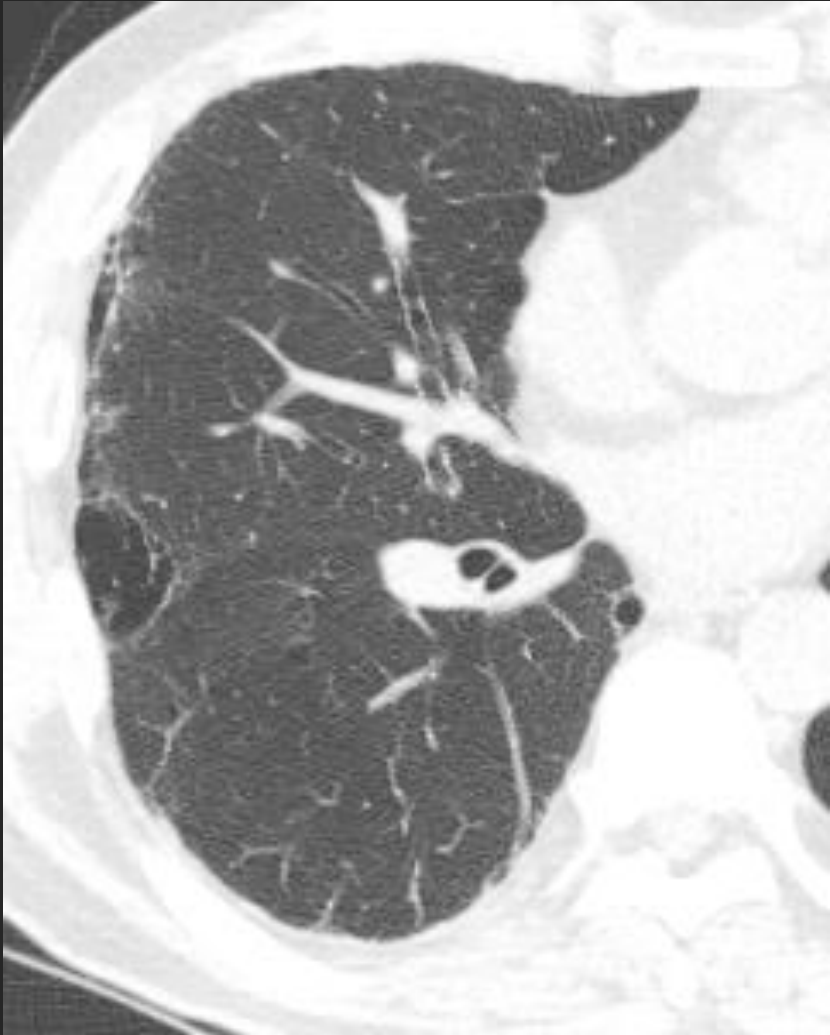**Let's Enjoy Dr Y's Chest Radiology**

**Mass; 3 YA,**

**3 MA,**

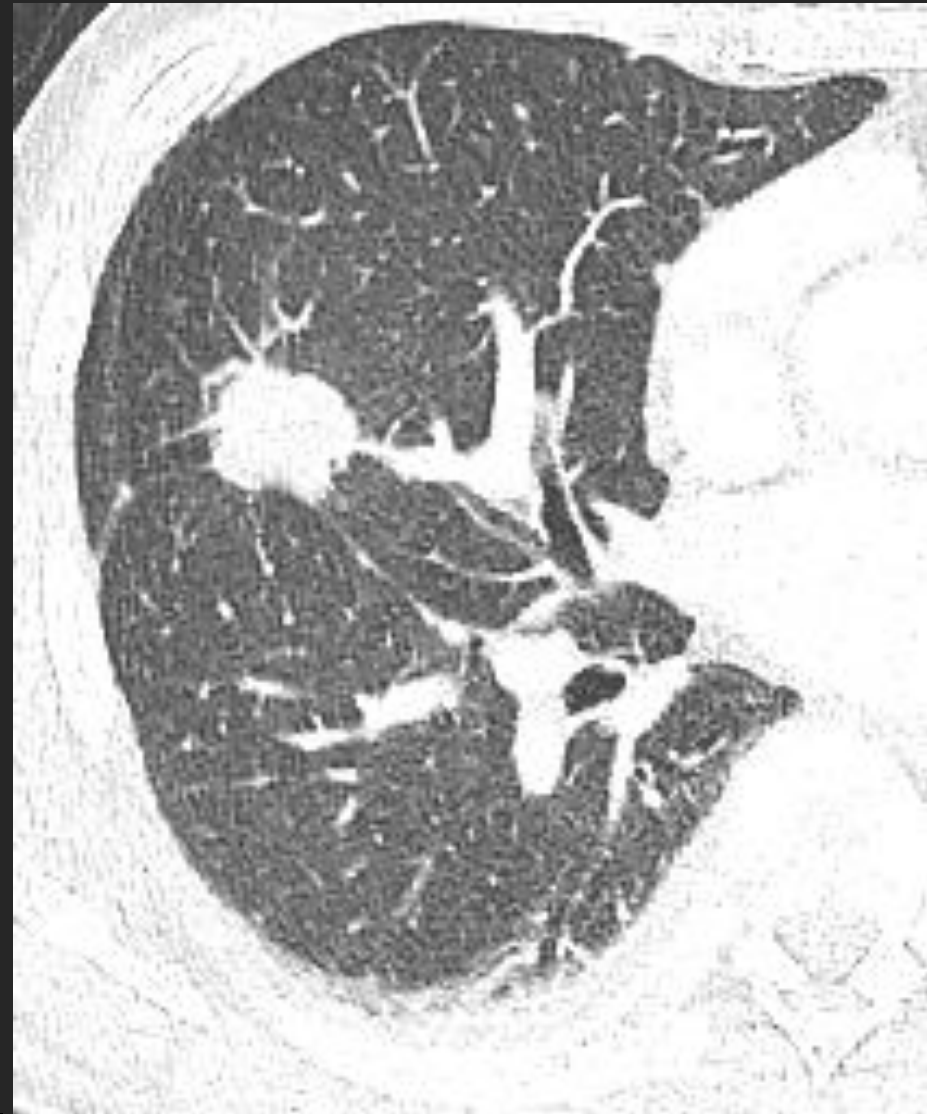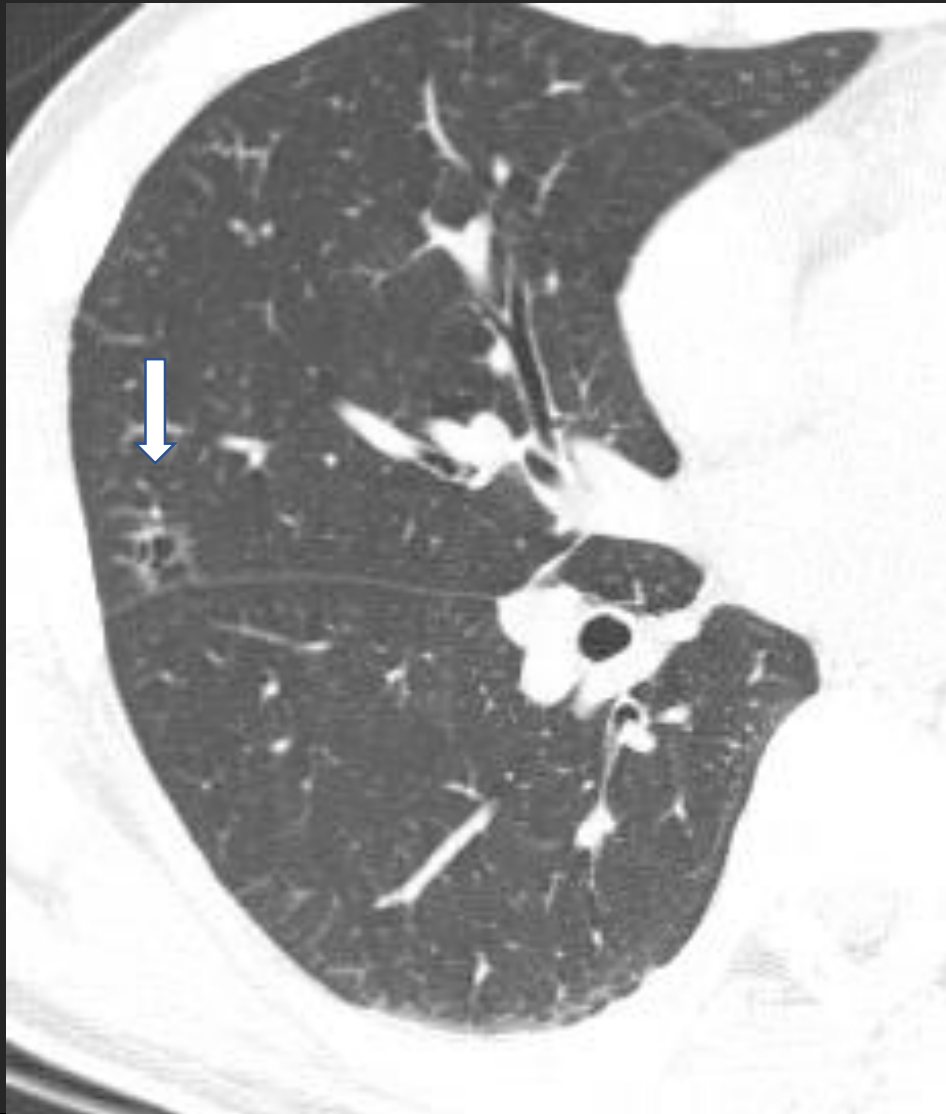
**Now**



**Let's Enjoy Dr Y's Chest Radiology**

Cyst,

10 YA



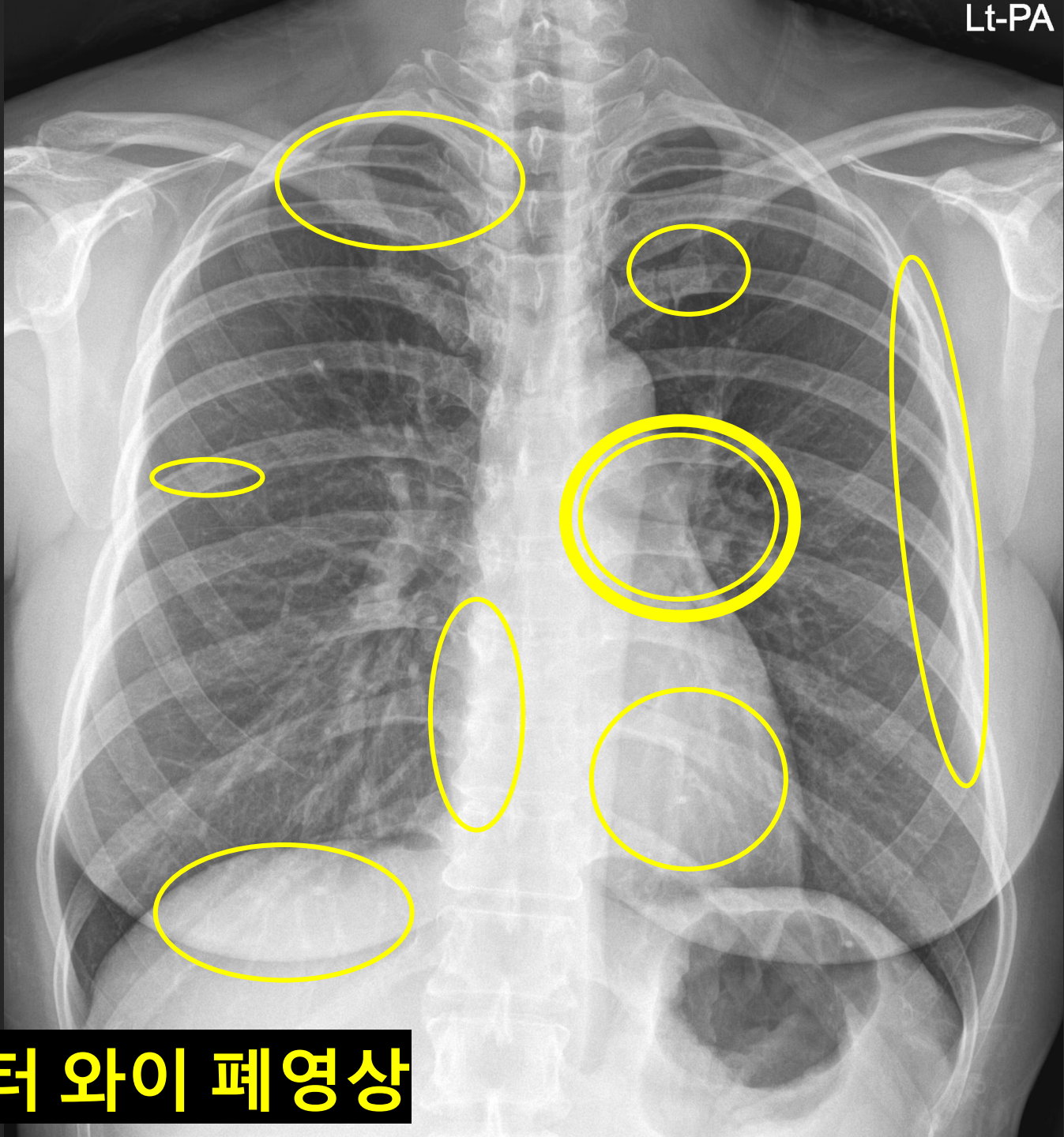
Let's Enjoy Dr Y's Chest Radiology

**A. Central type**

**B. Peripheral type**

**C. “Missed” lung cancer**

**D. New or Grow : 무섭다**

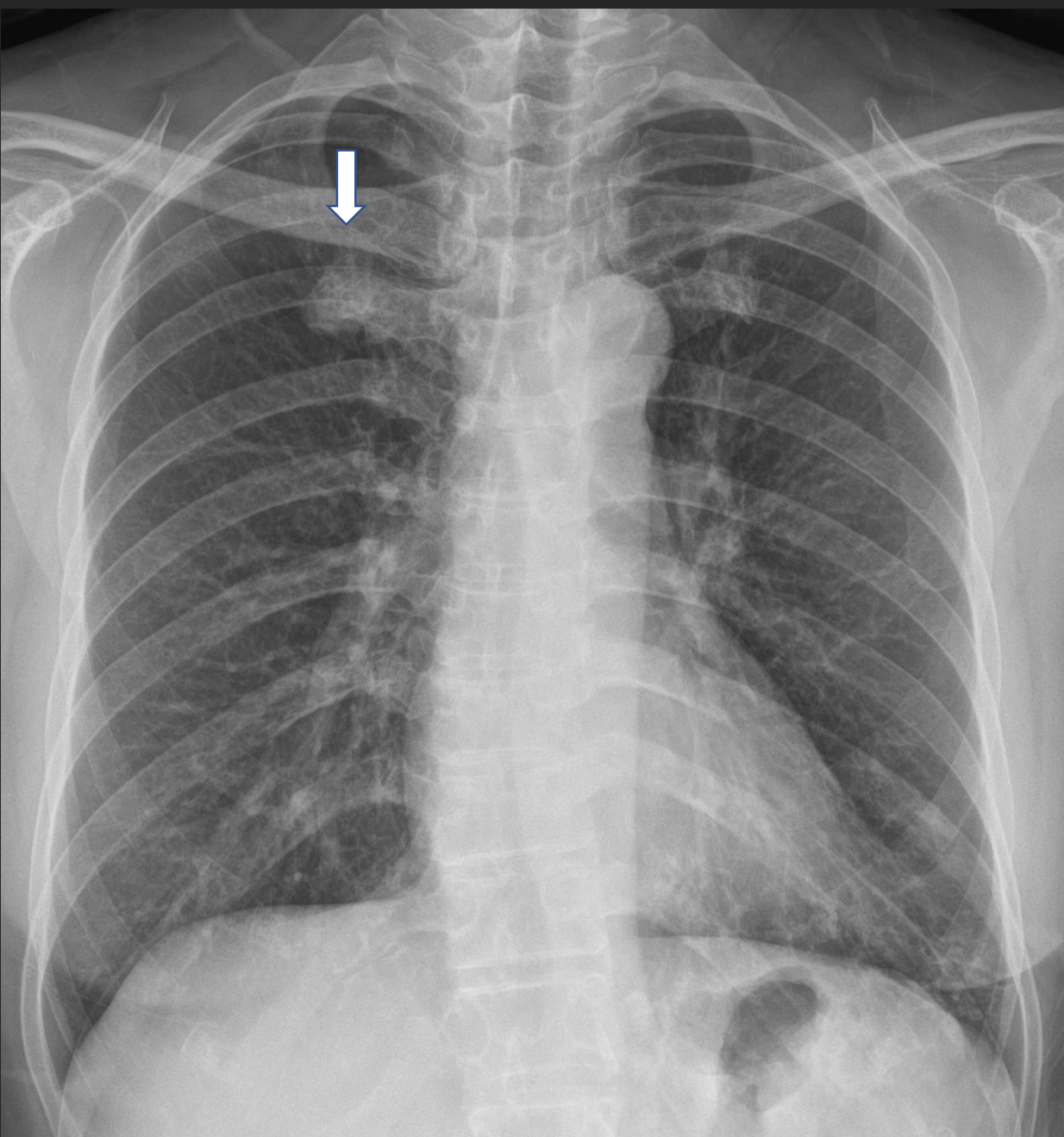


**Ambush**

**Easy to miss**

**Let's Enjoy 닥터 와이 폐영상**

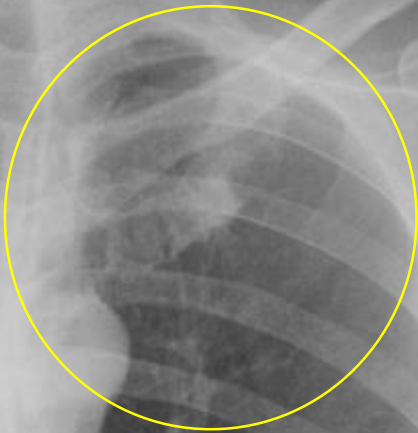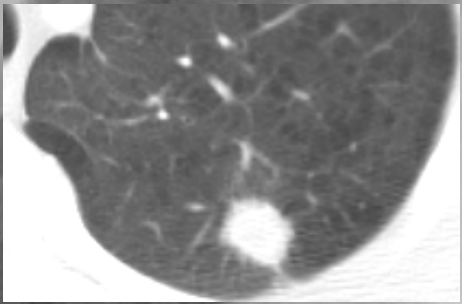




**Student tumor**  
**1<sup>st</sup> costochondral junction**  
**Normal**

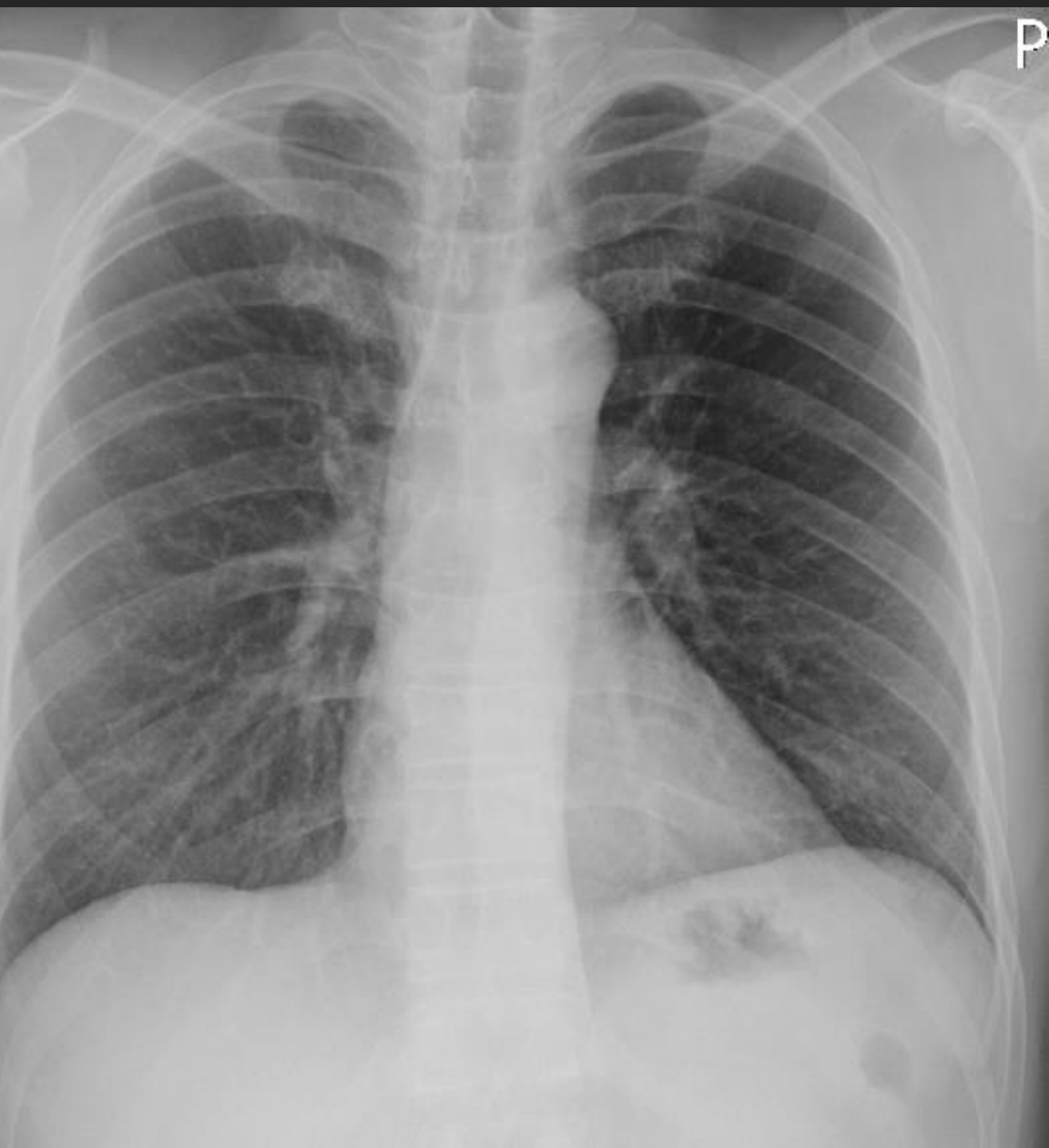**Let's Enjoy the Chest Radiograph with Dr. Y.**

**3 YA**

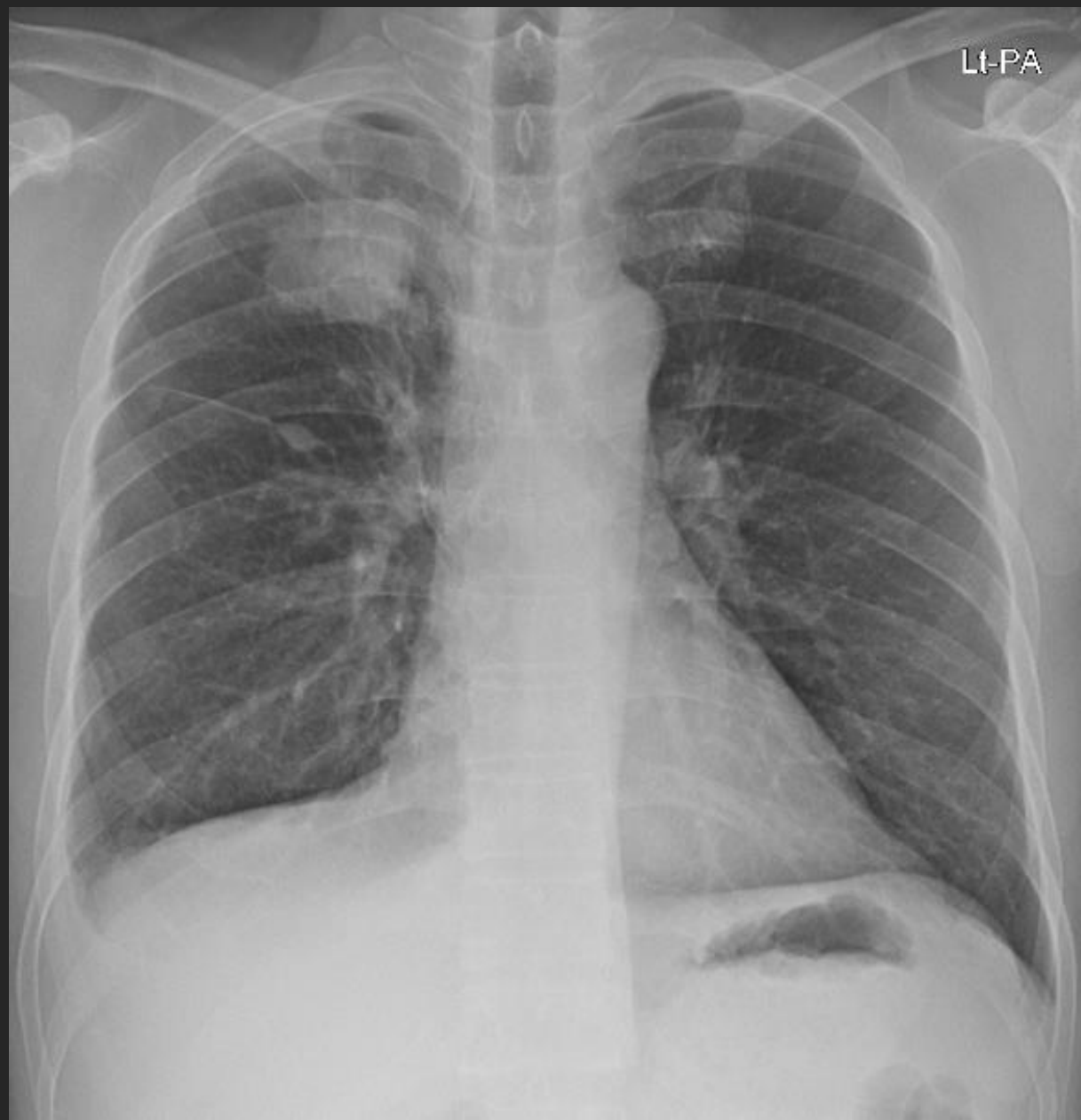


**Let's Enjoy 닥터 와이 폐영상**

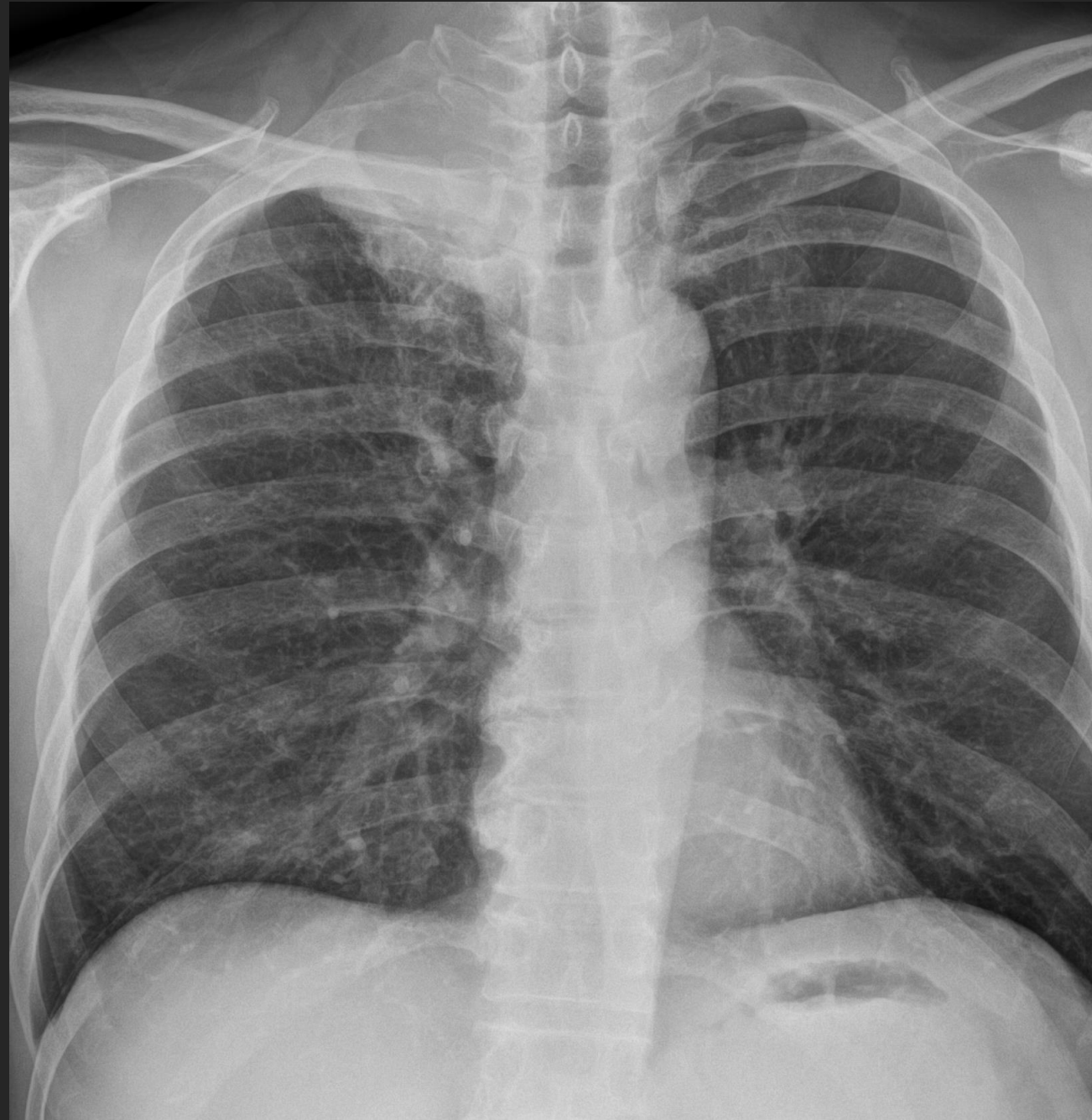2 YA



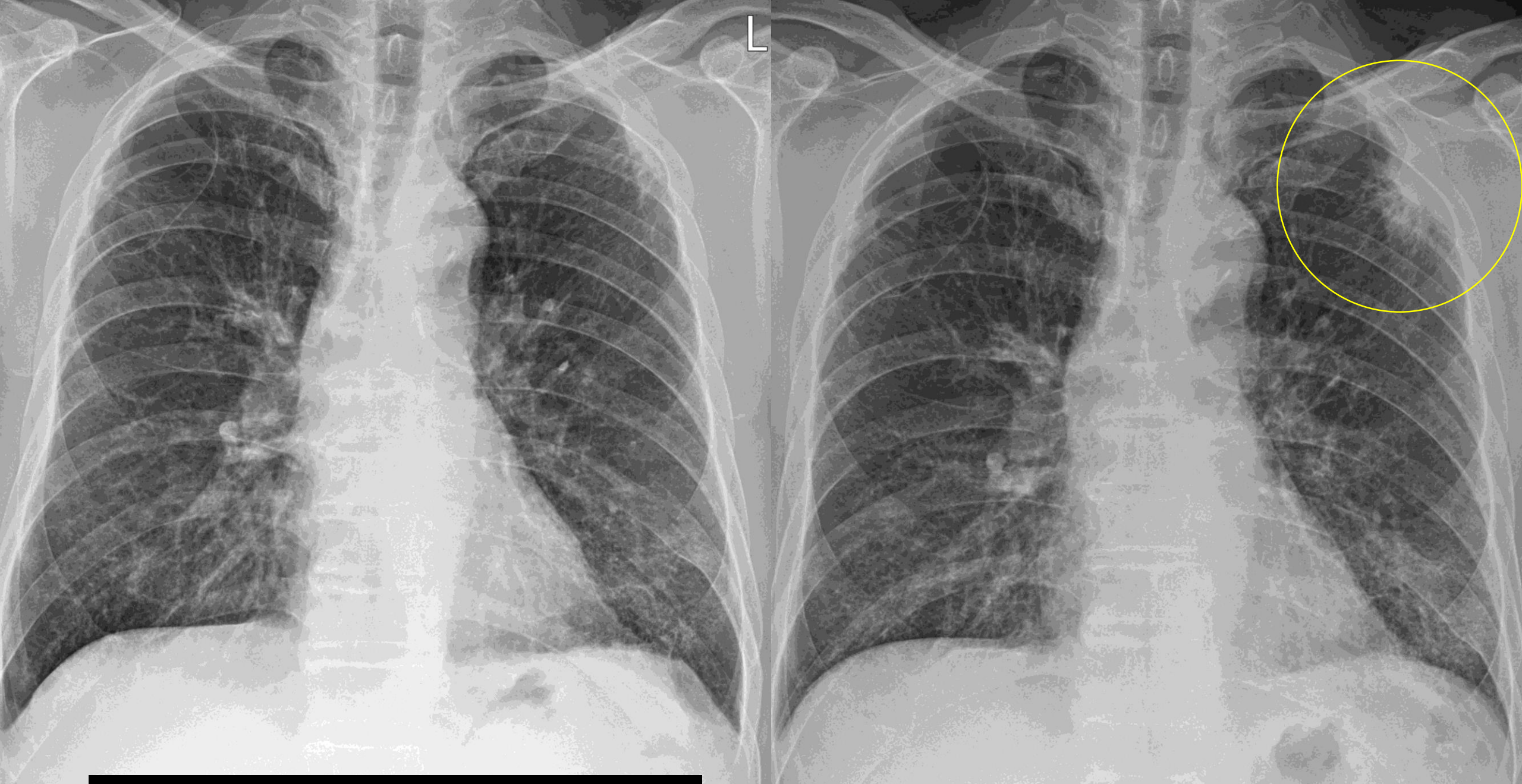
오늘



# Superior sulcus tumor, SCC

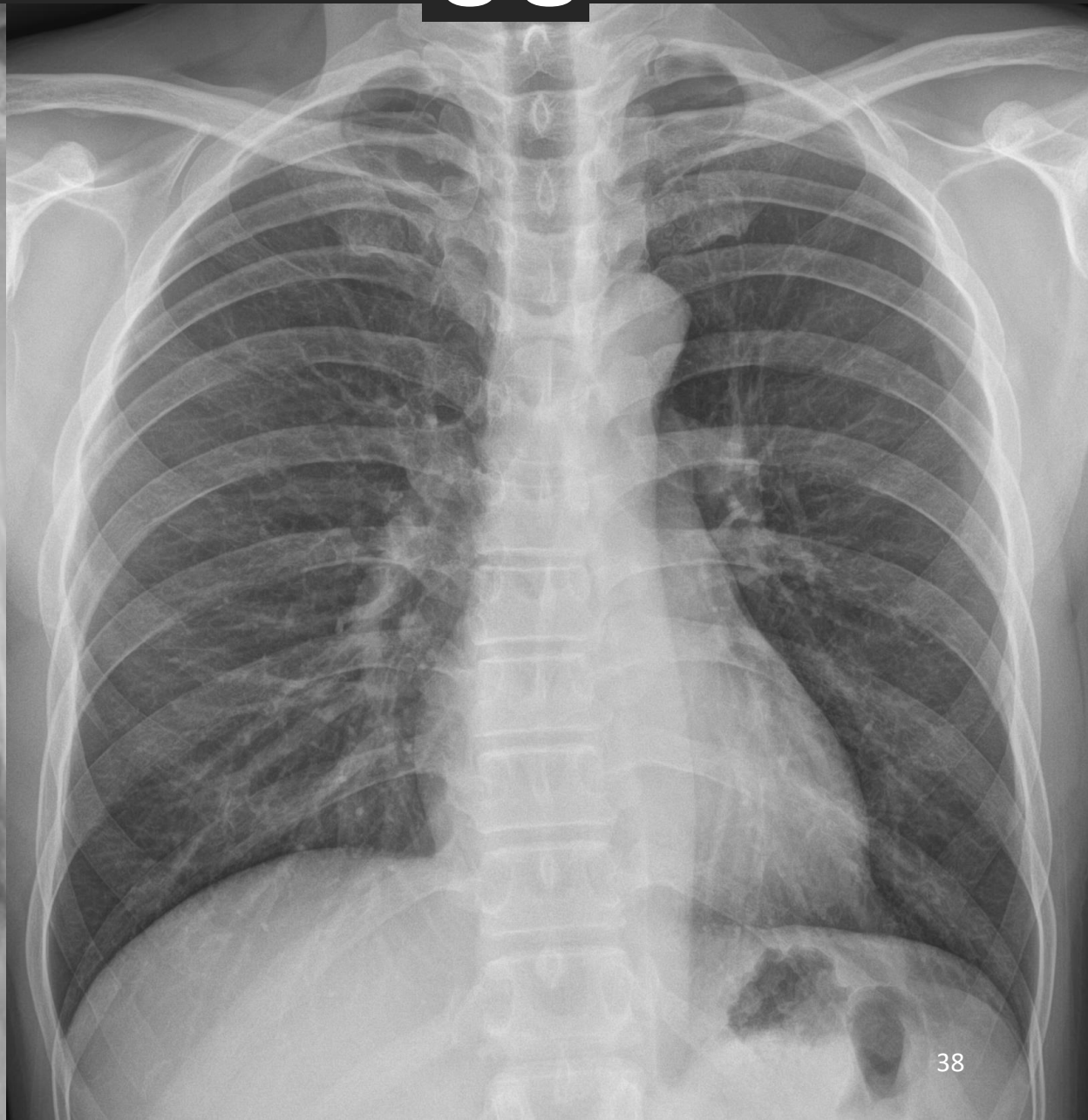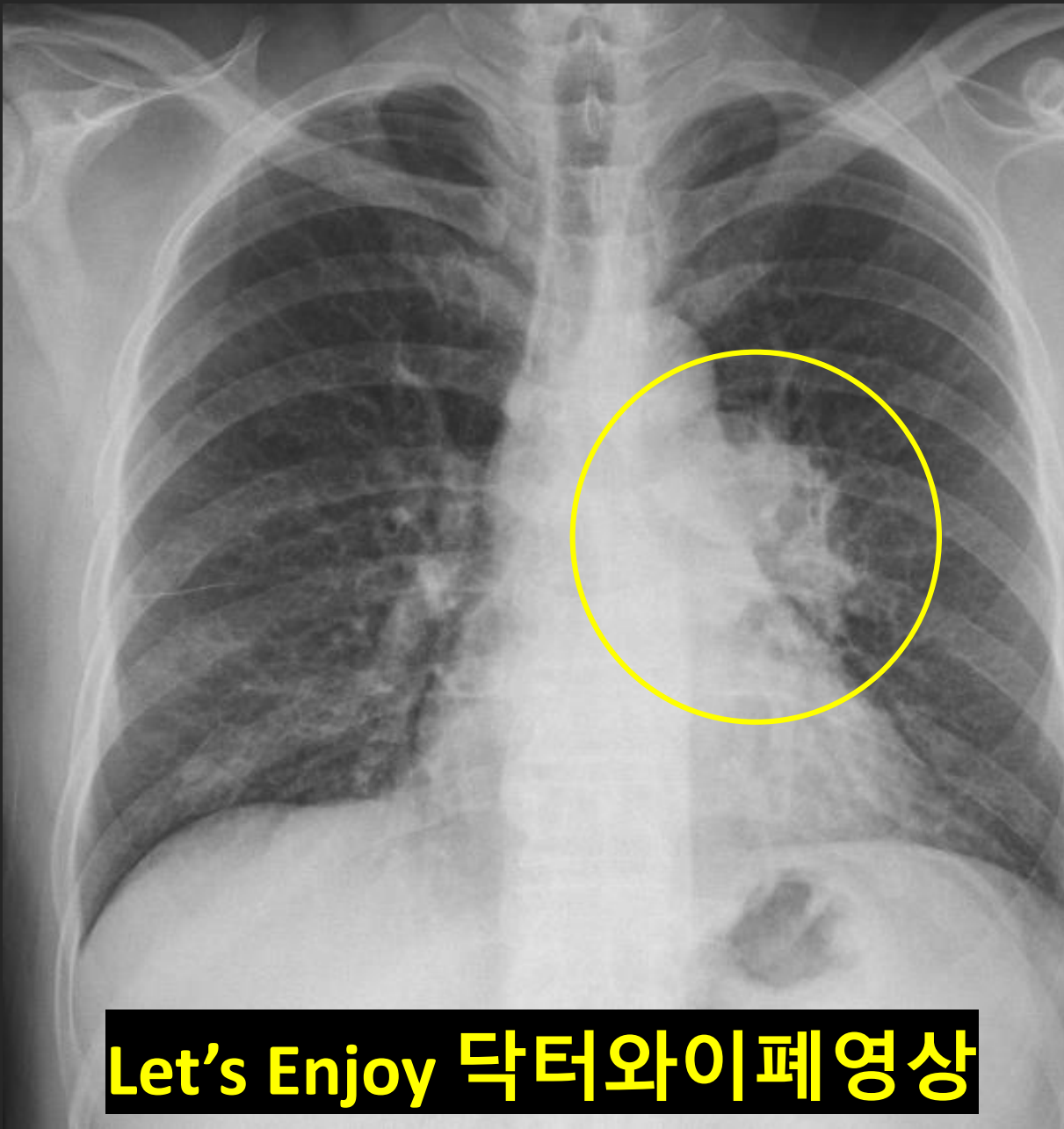


Let's Enjoy 닥터 와이 폐영상



**Let's Enjoy 닥터 와이 폐영상**

정상



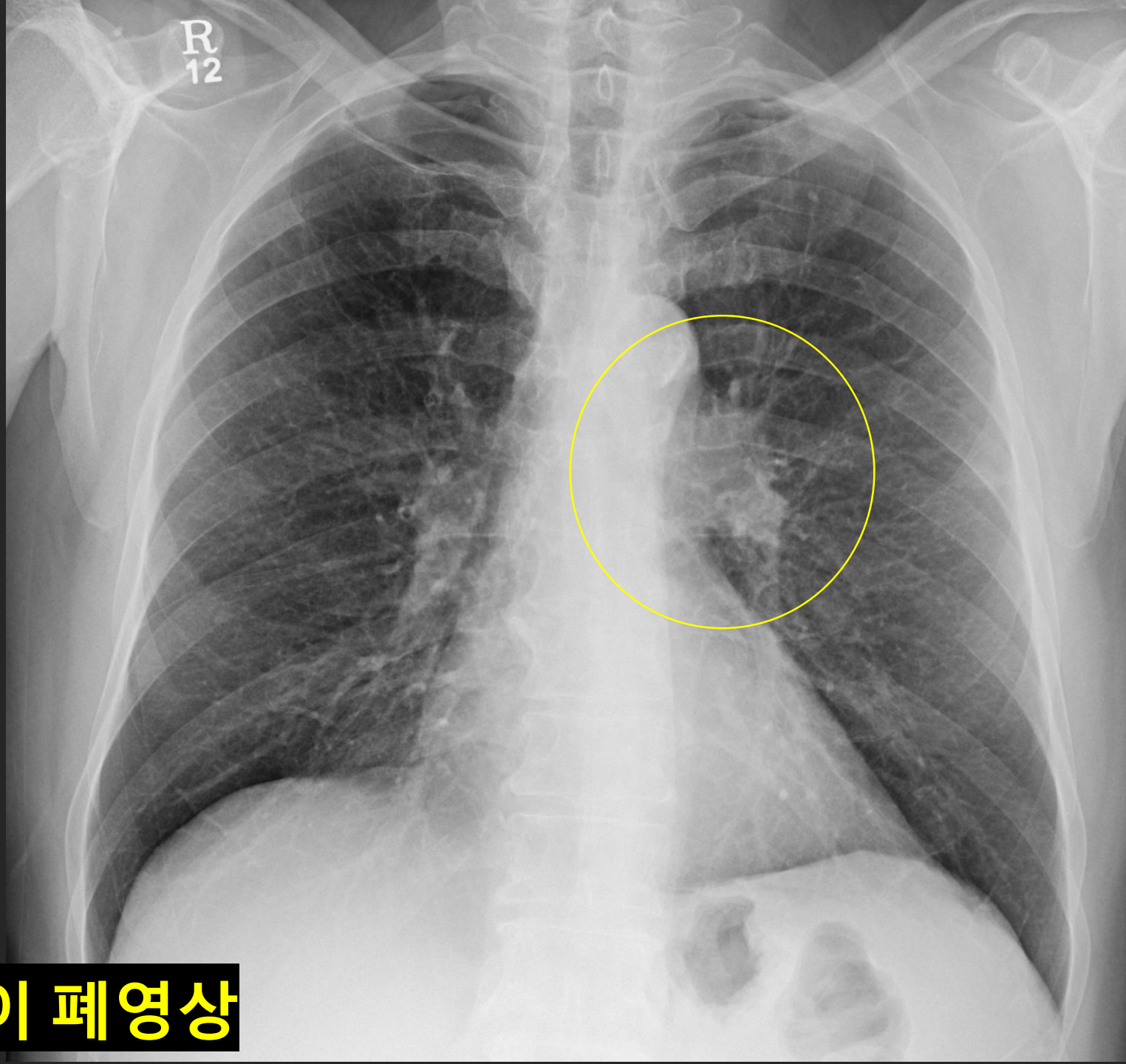
Let's Enjoy 닥터와이폐영상

肺門;

반대쪽보다,

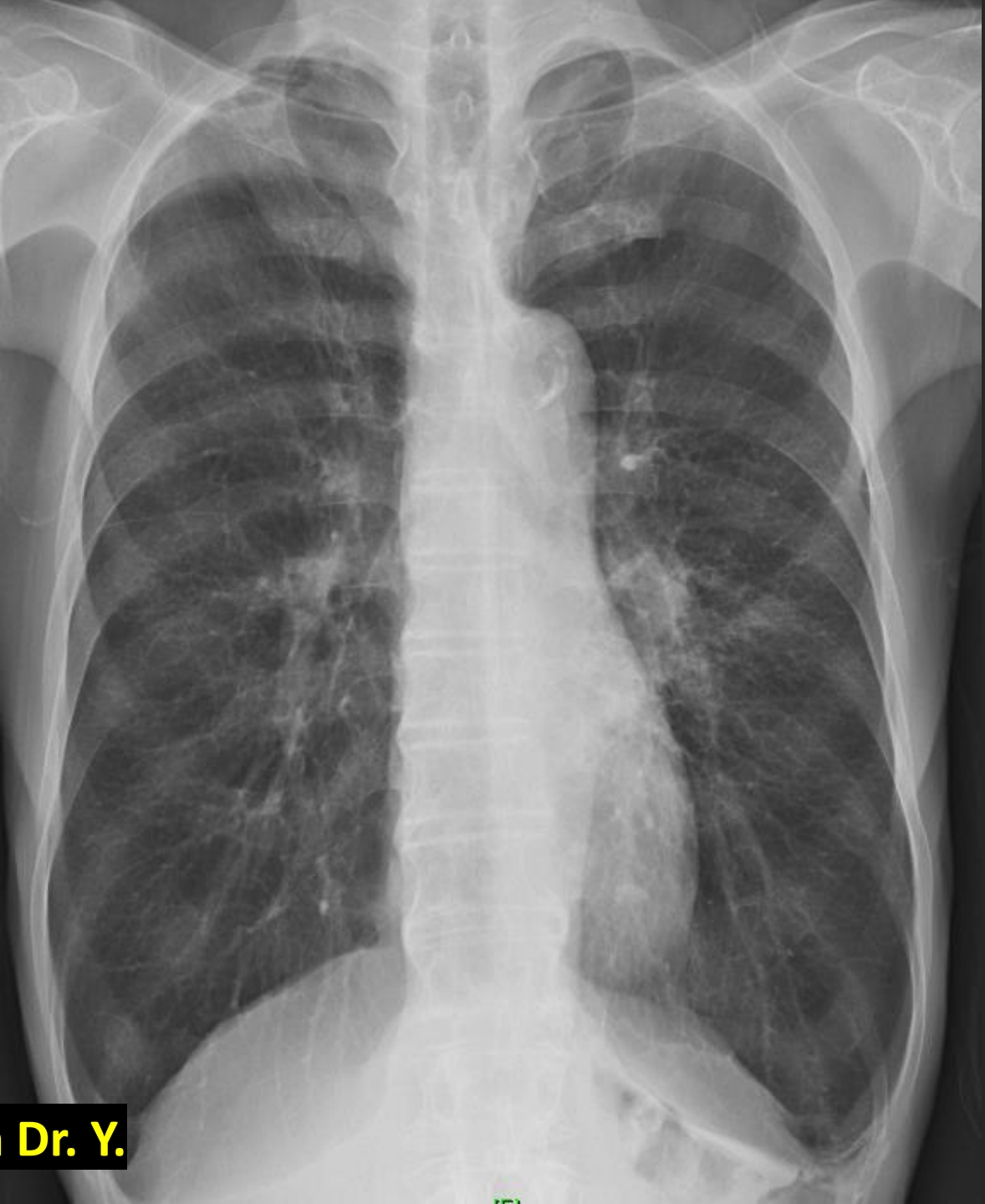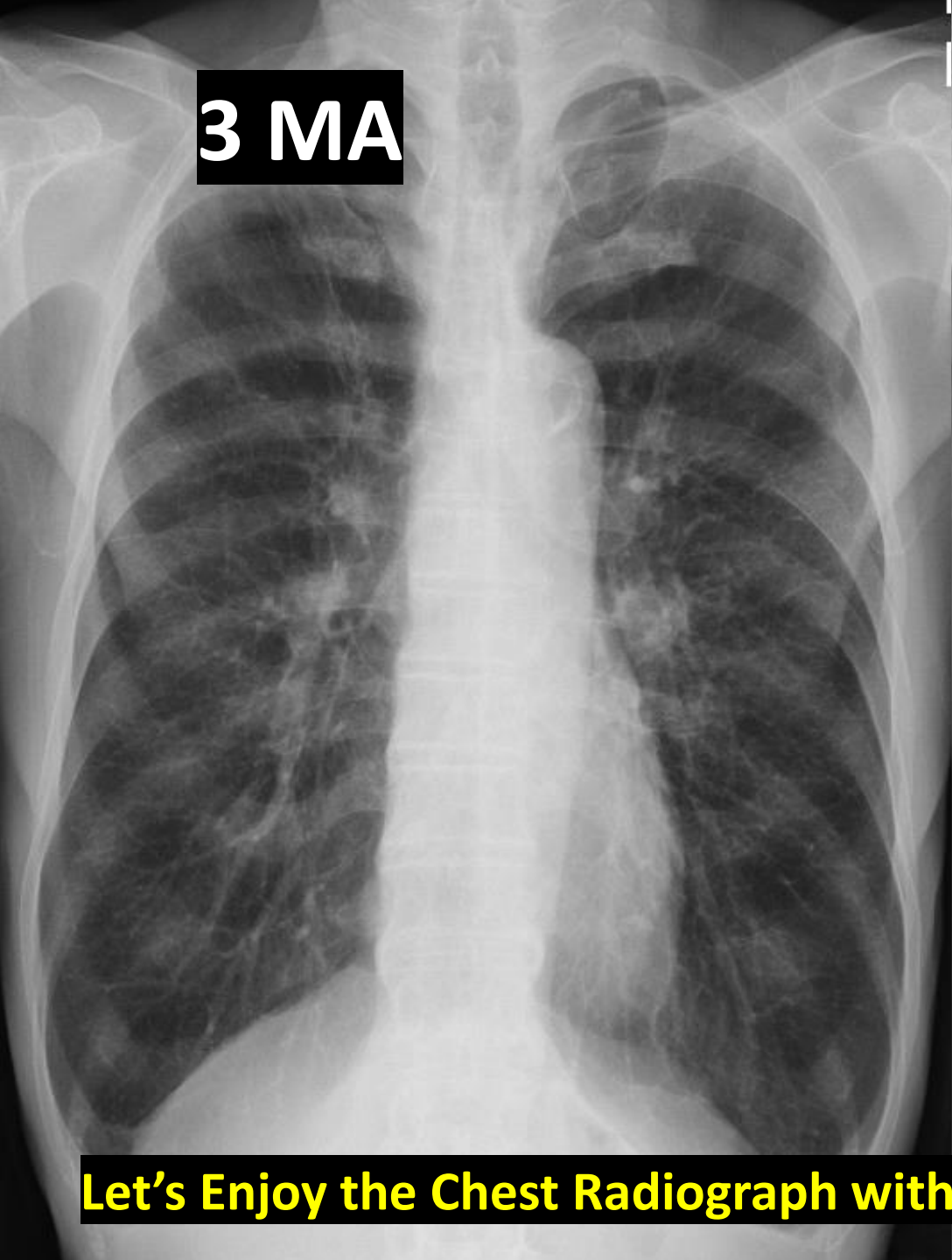
진하다  
조금 크다

PA, Br. 경계가 애매



Let's Enjoy 닥터 와이 폐영상

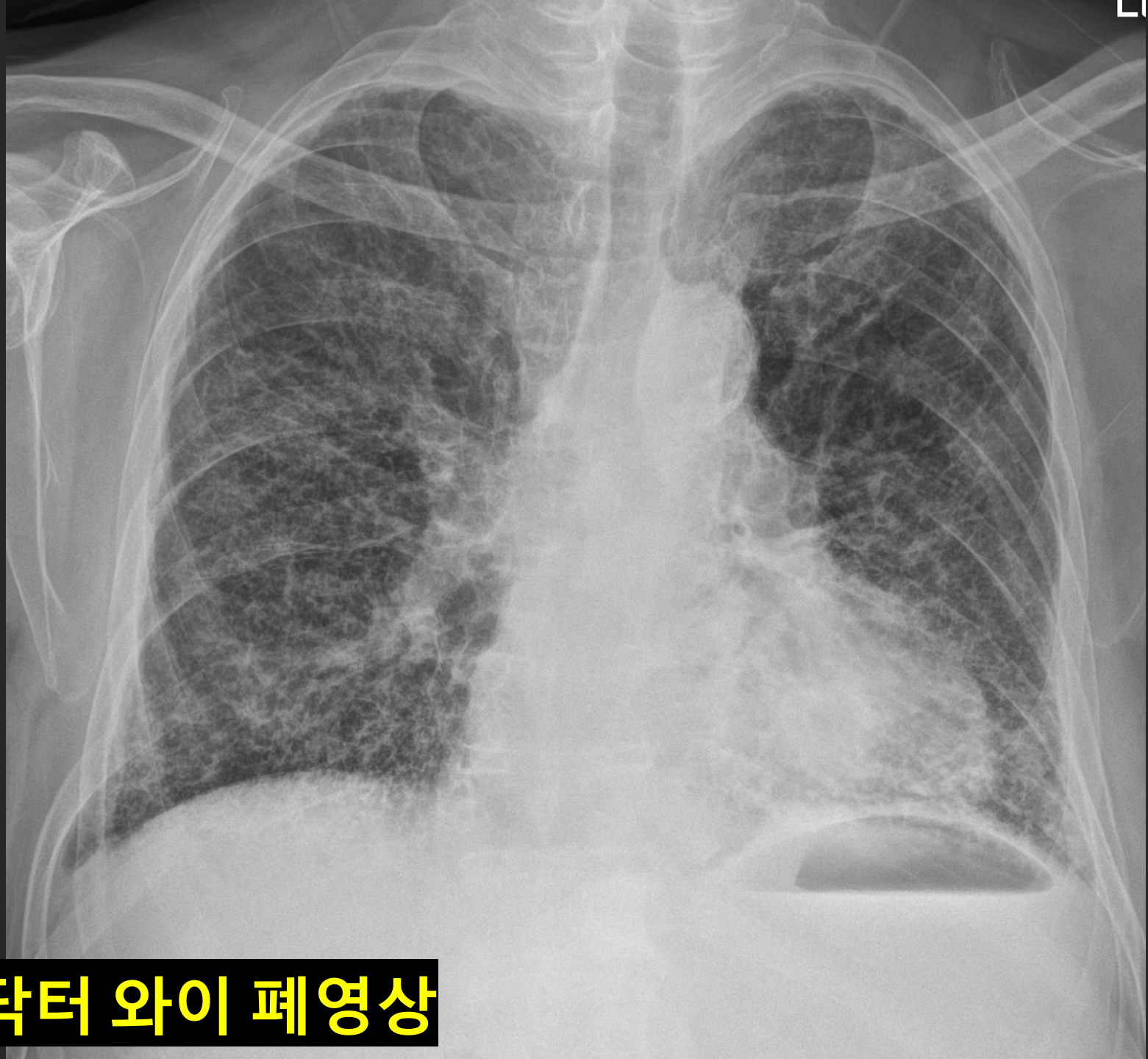
**3 MA**



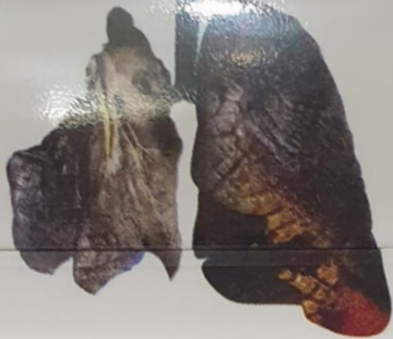**Let's Enjoy the Chest Radiograph with Dr. Y.**







**Let's Enjoy 닥터 와이 폐영상**



# 폐암

금연상담전화 1544-9030



냄새저감



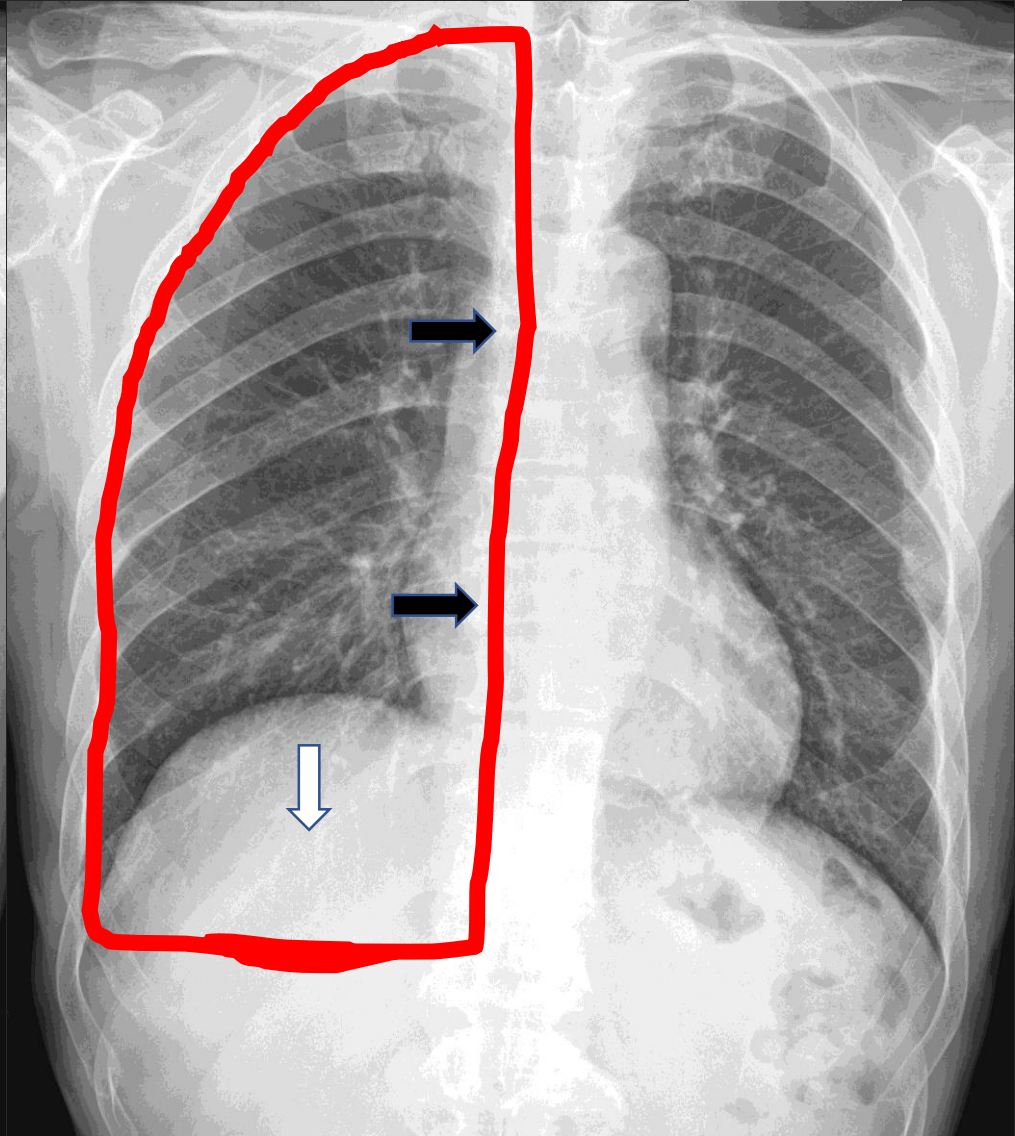
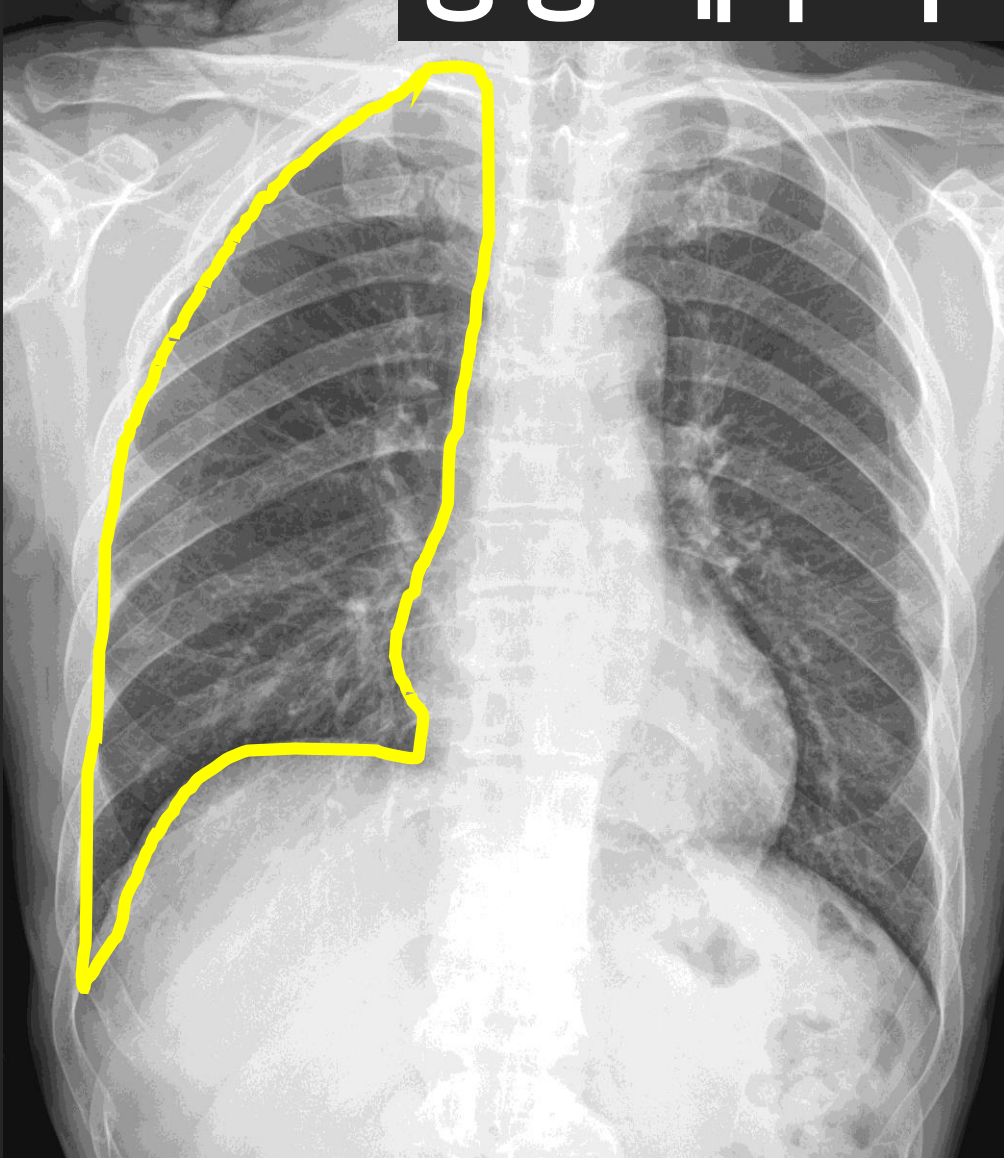
FINE CUT  
1MG

파인컷 1MG

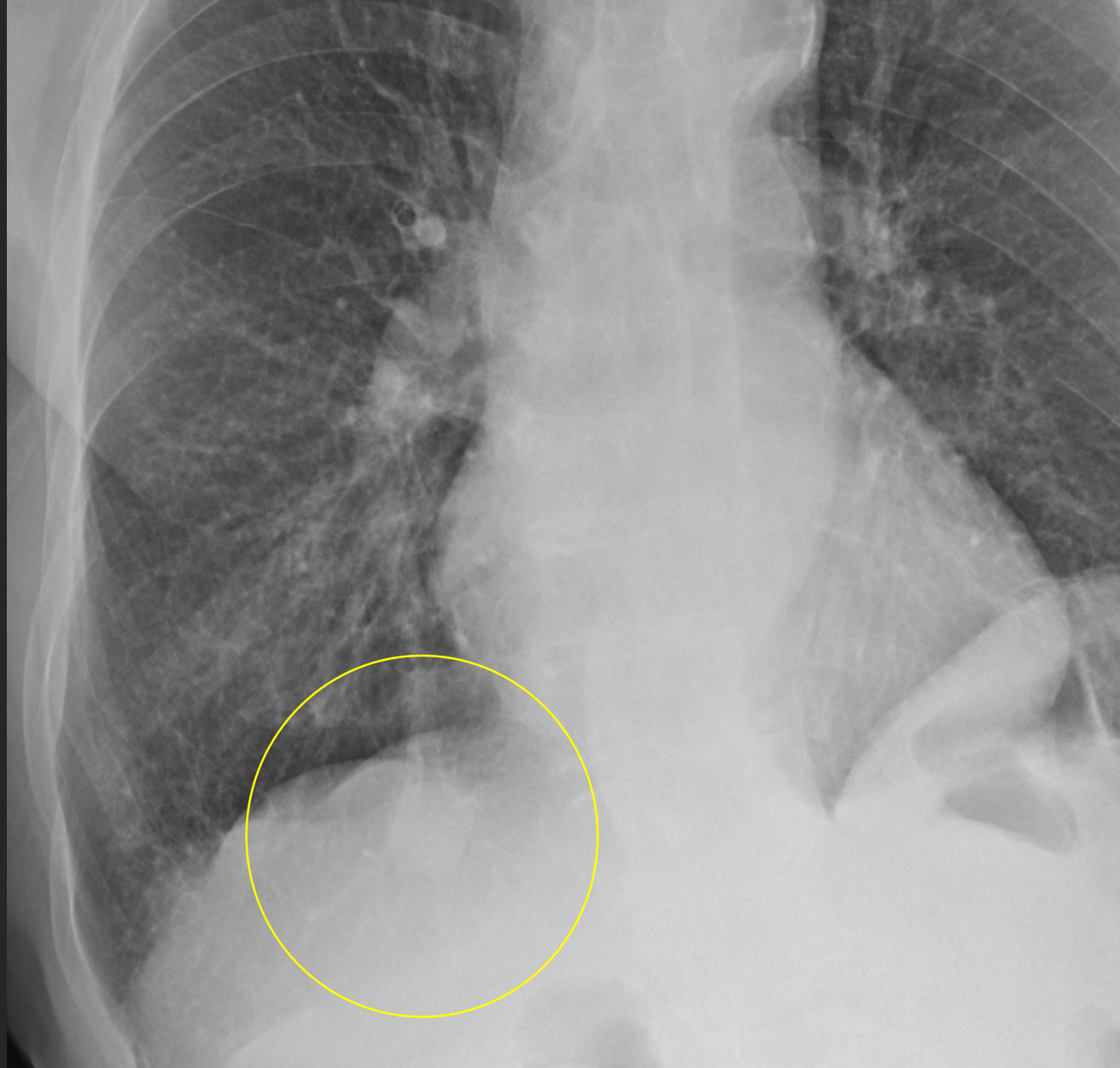
4,500원

Let's Enjoy Dr Y's C

# 정상 해부학 사진 2; 허파는 어디까지 ?

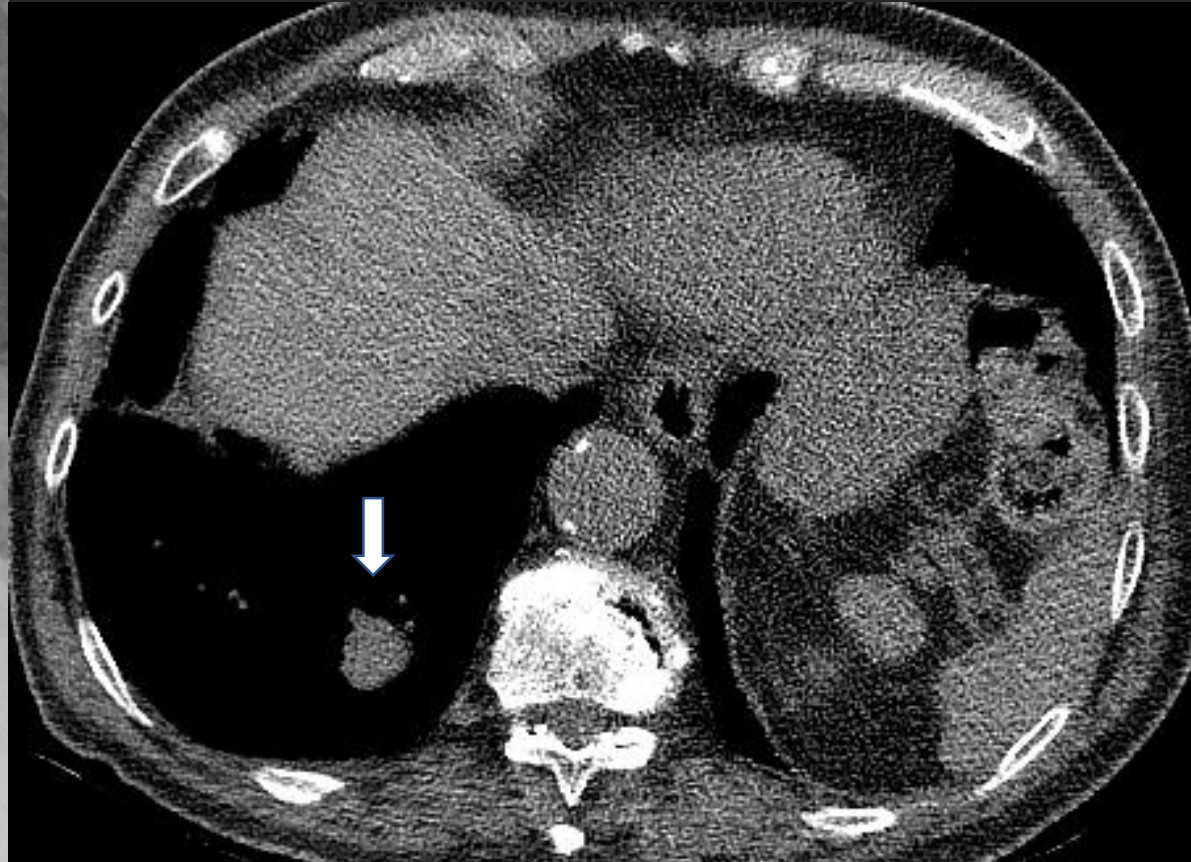


Let's Enjoy 닥터 와이 폐영상

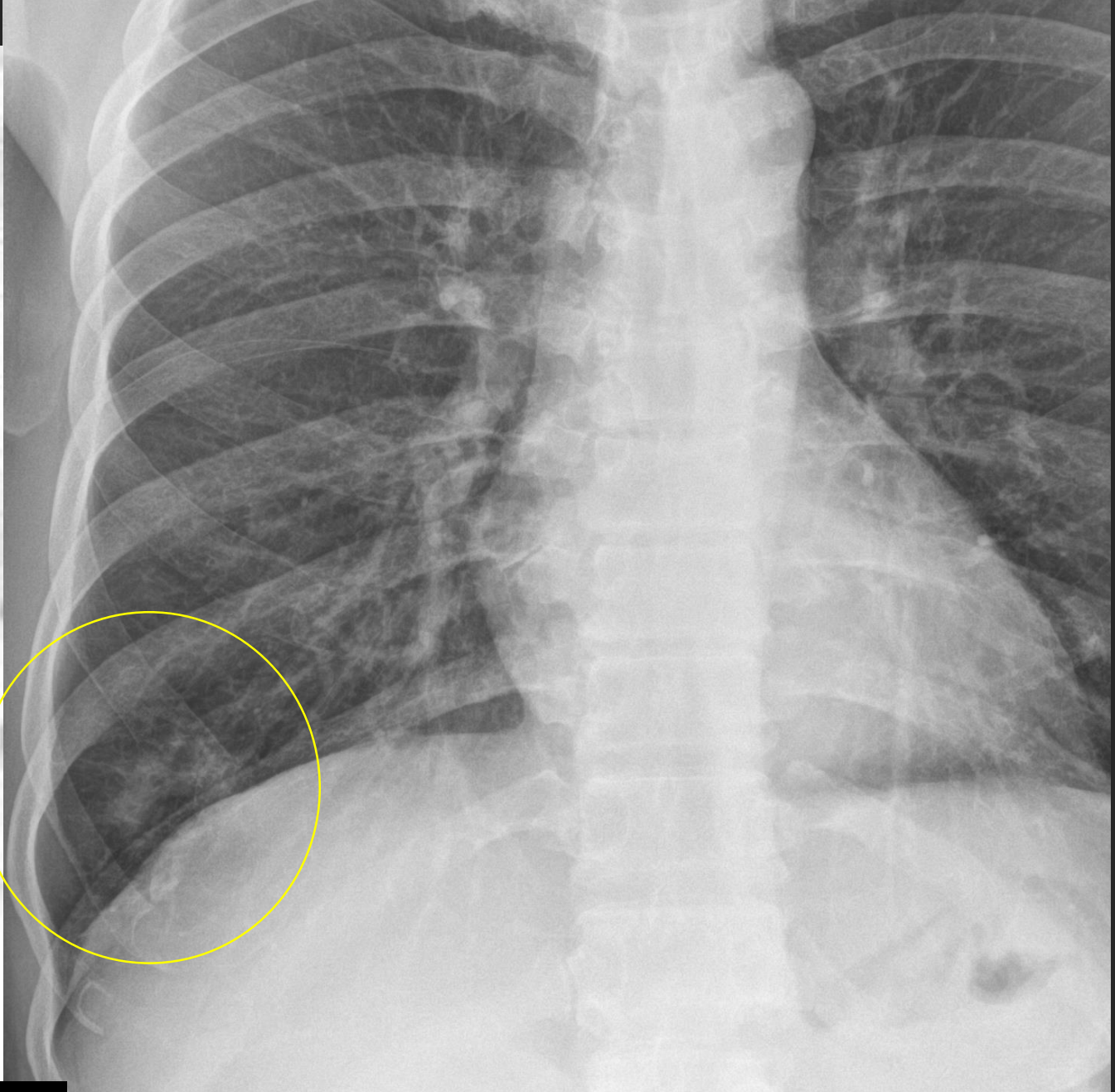
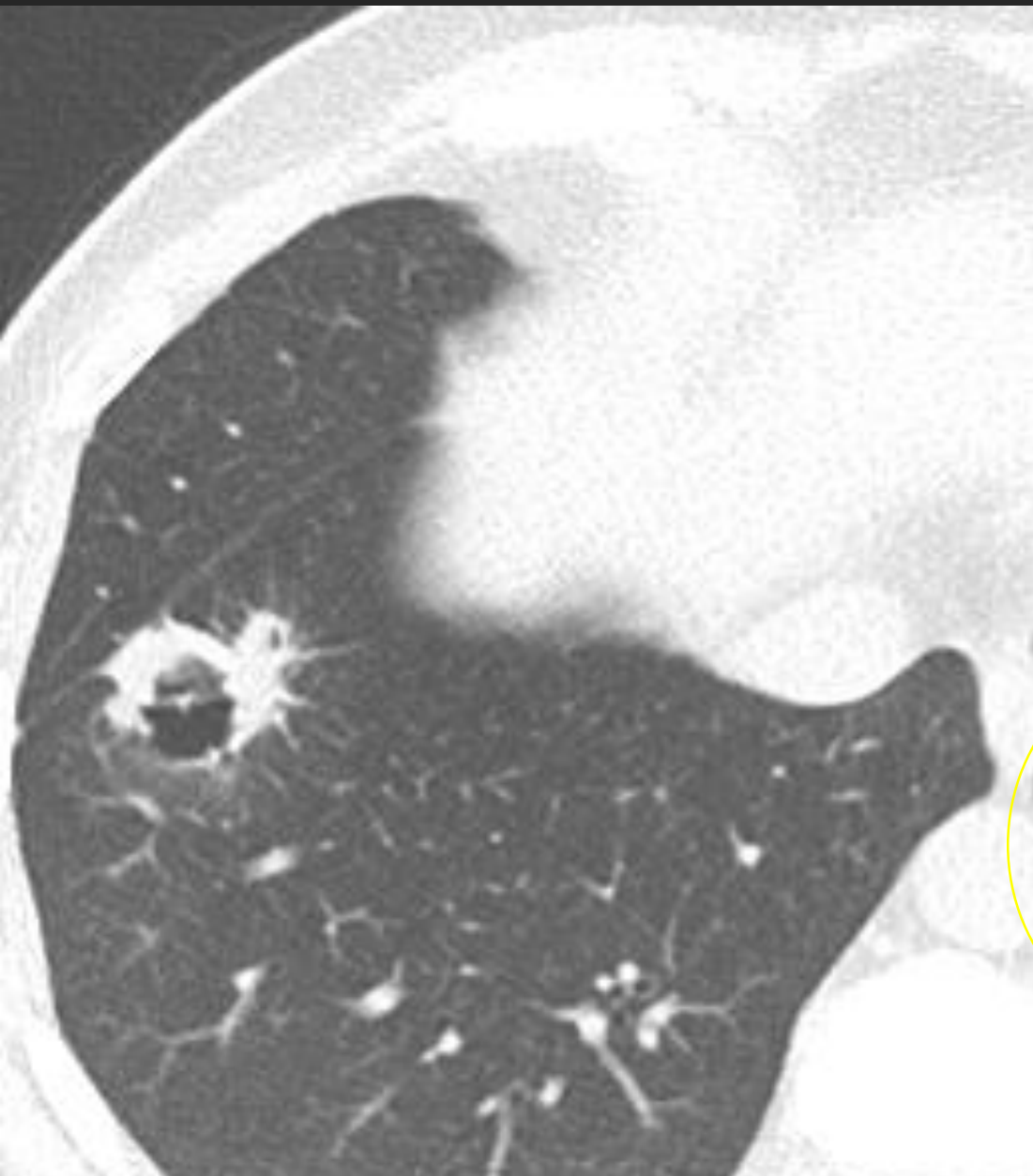


**RLL SPN**

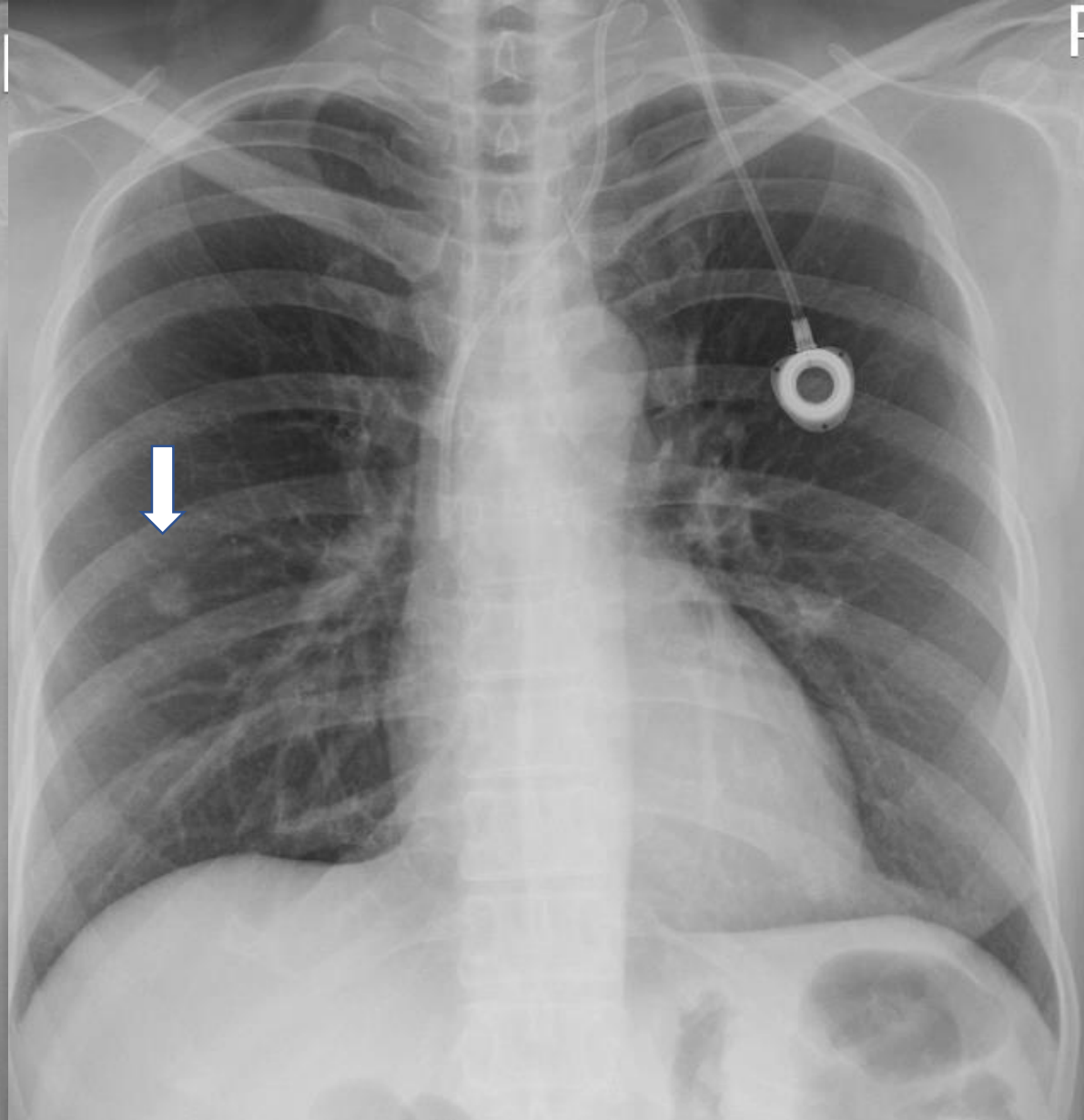
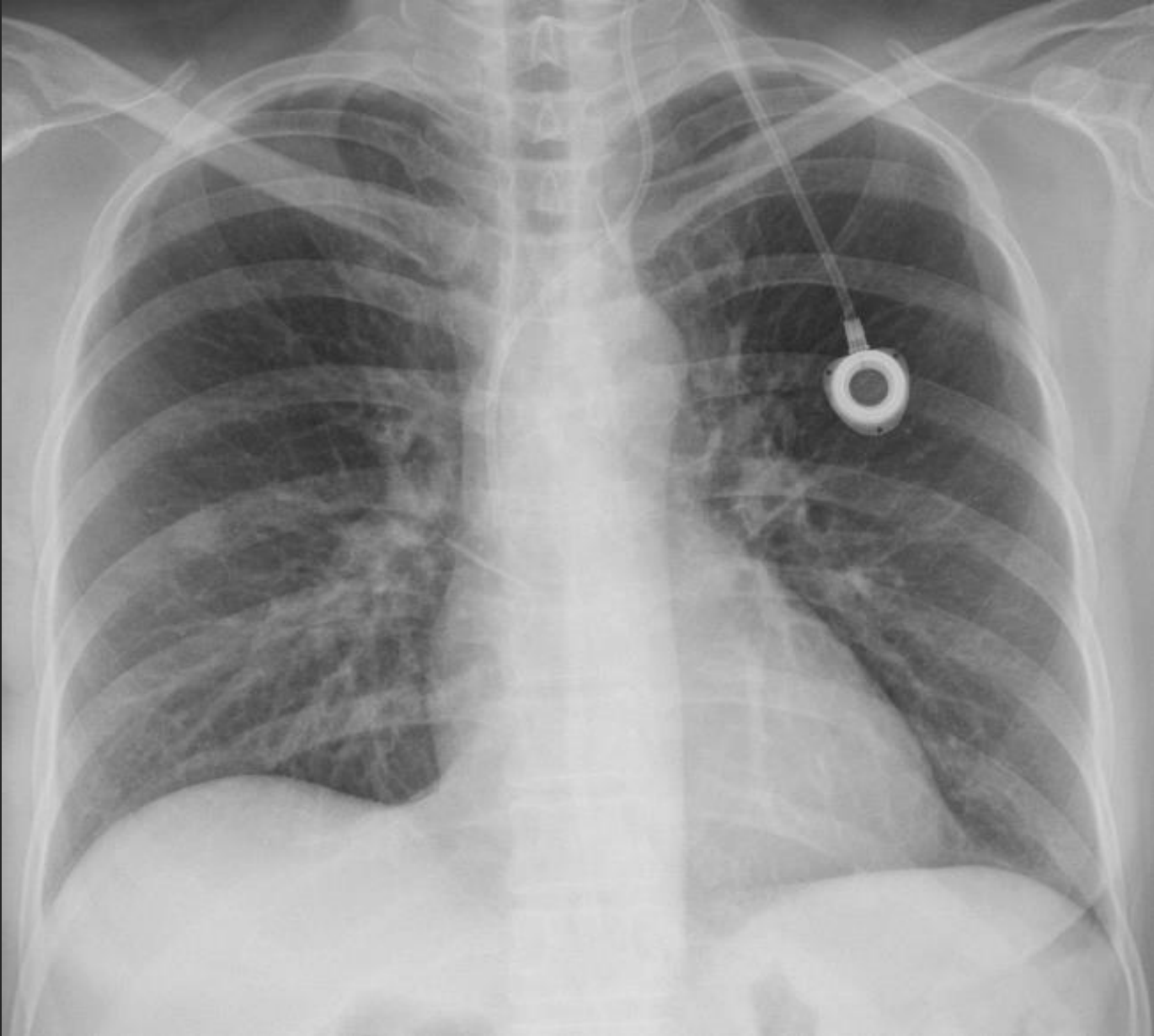**Infra-diaphragmatic**



**Let's Enjoy 닥터 와이 폐영상**

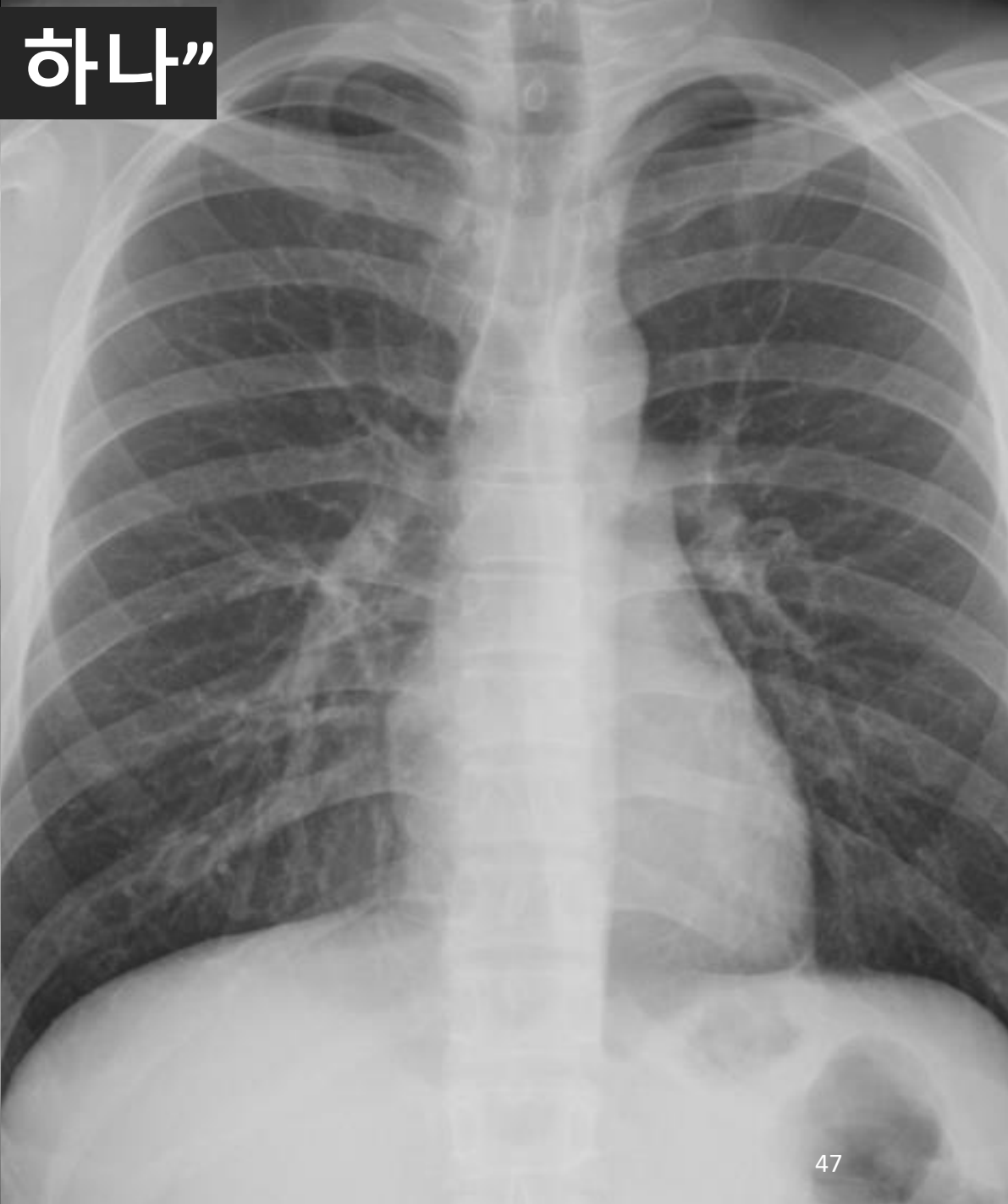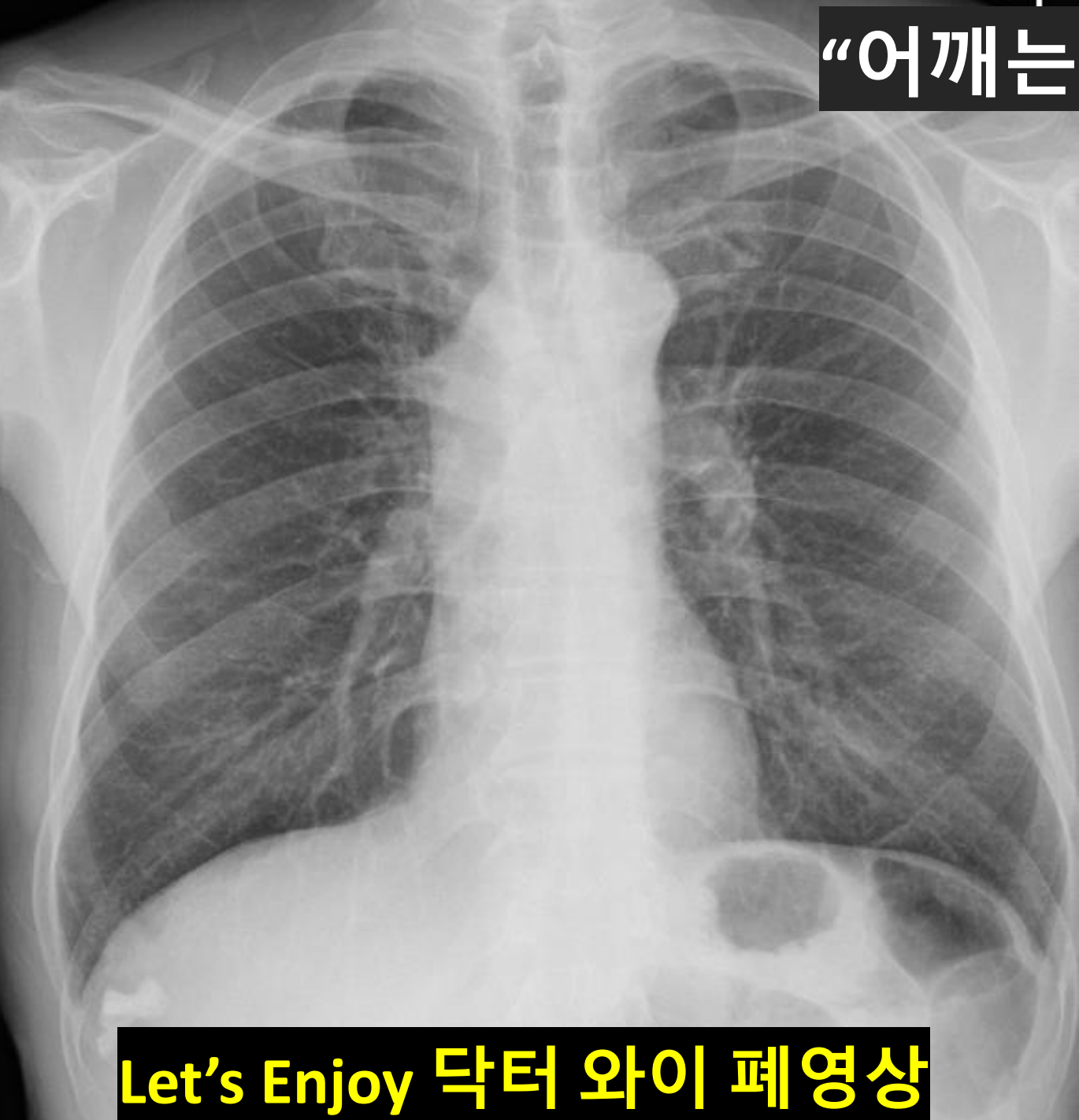


**Let's Enjoy 닥터 와이 폐영상**



**Let's Enjoy 닥터 와이 폐영상**

“어깨는 하나”

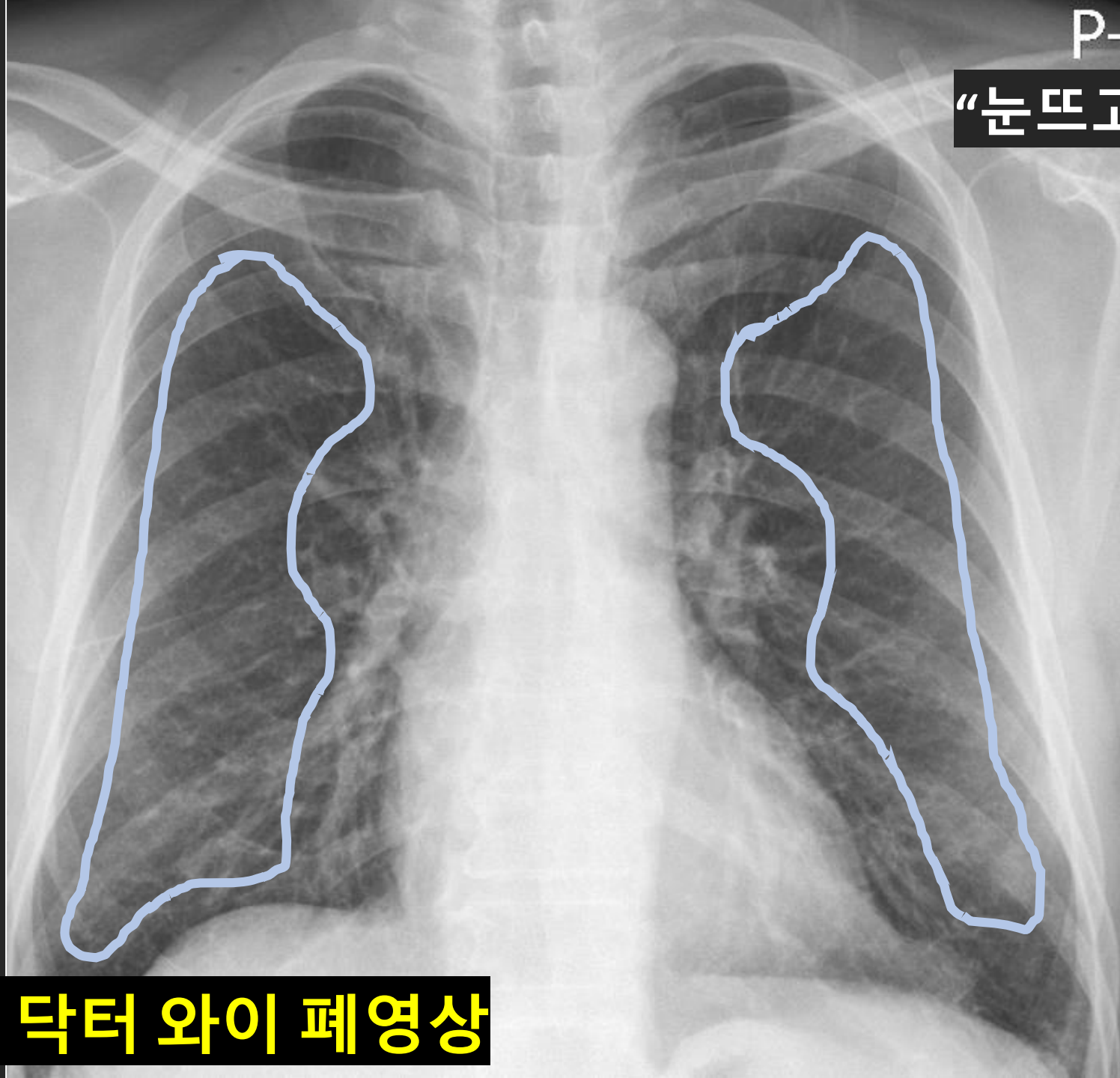


Let's Enjoy 닥터 와이 폐영상

Open field

Easy

But,  
GGN ?

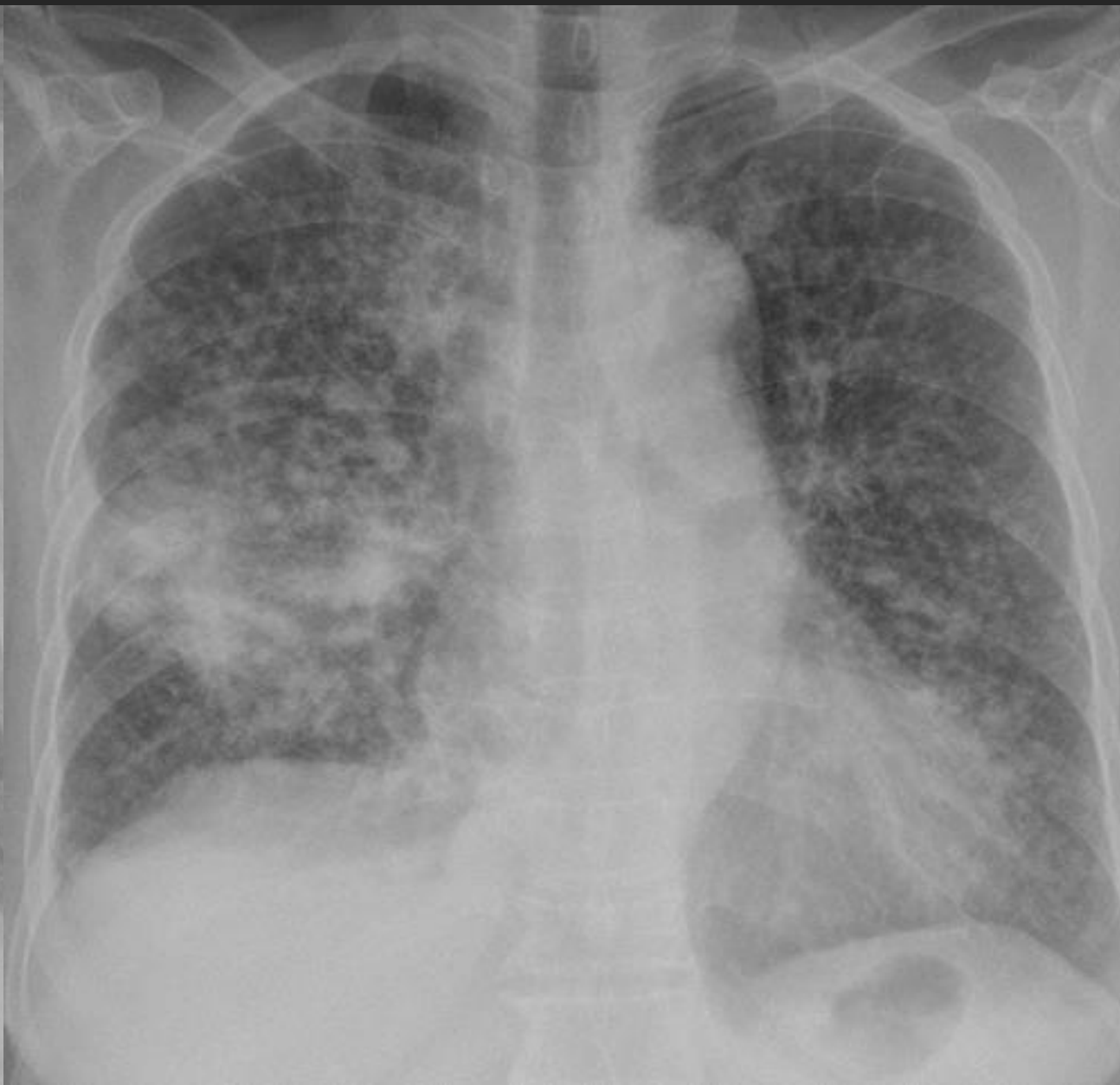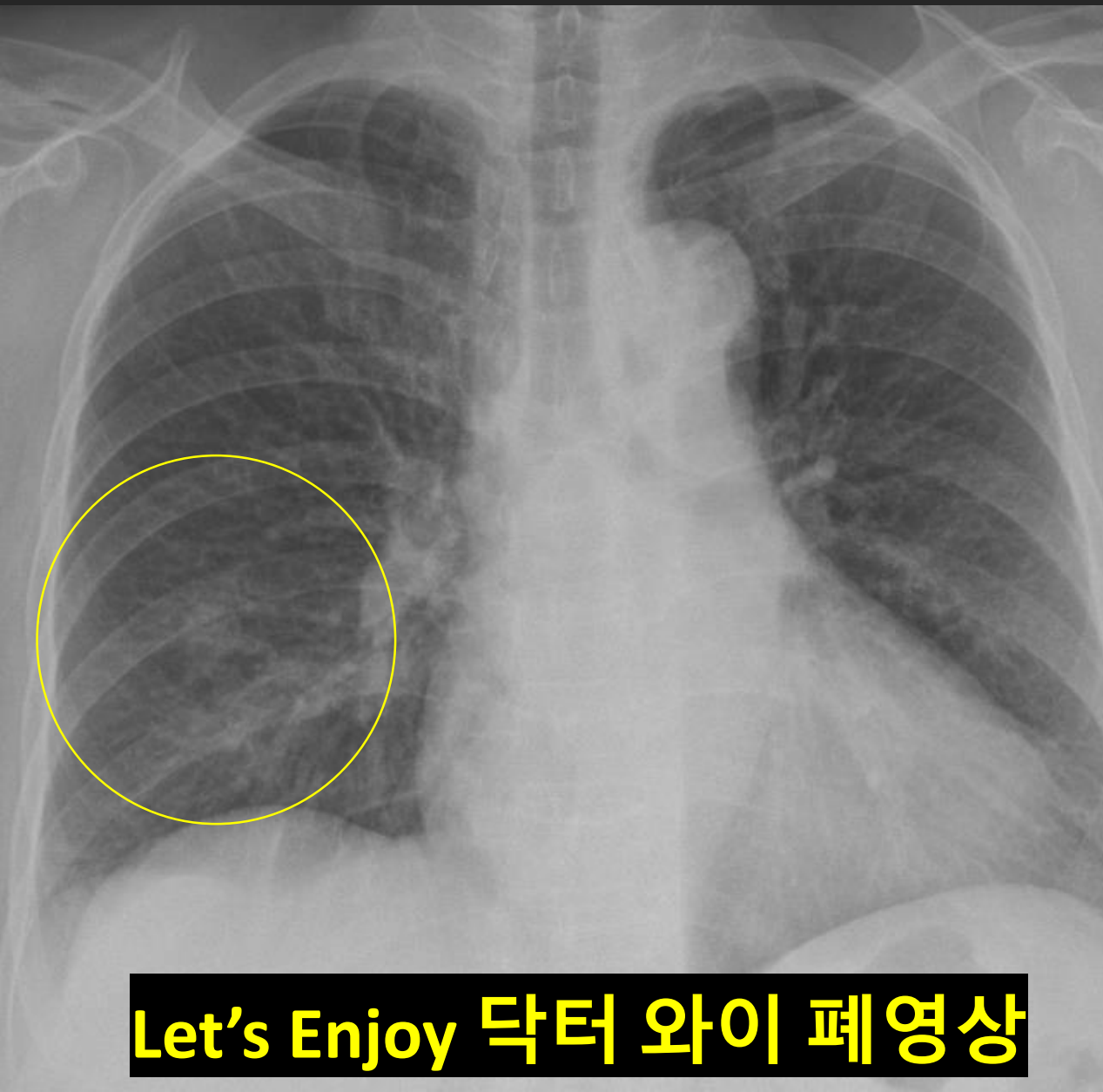


“눈뜨고 코 베어가는”

Let's Enjoy 닥터 와이 폐영상

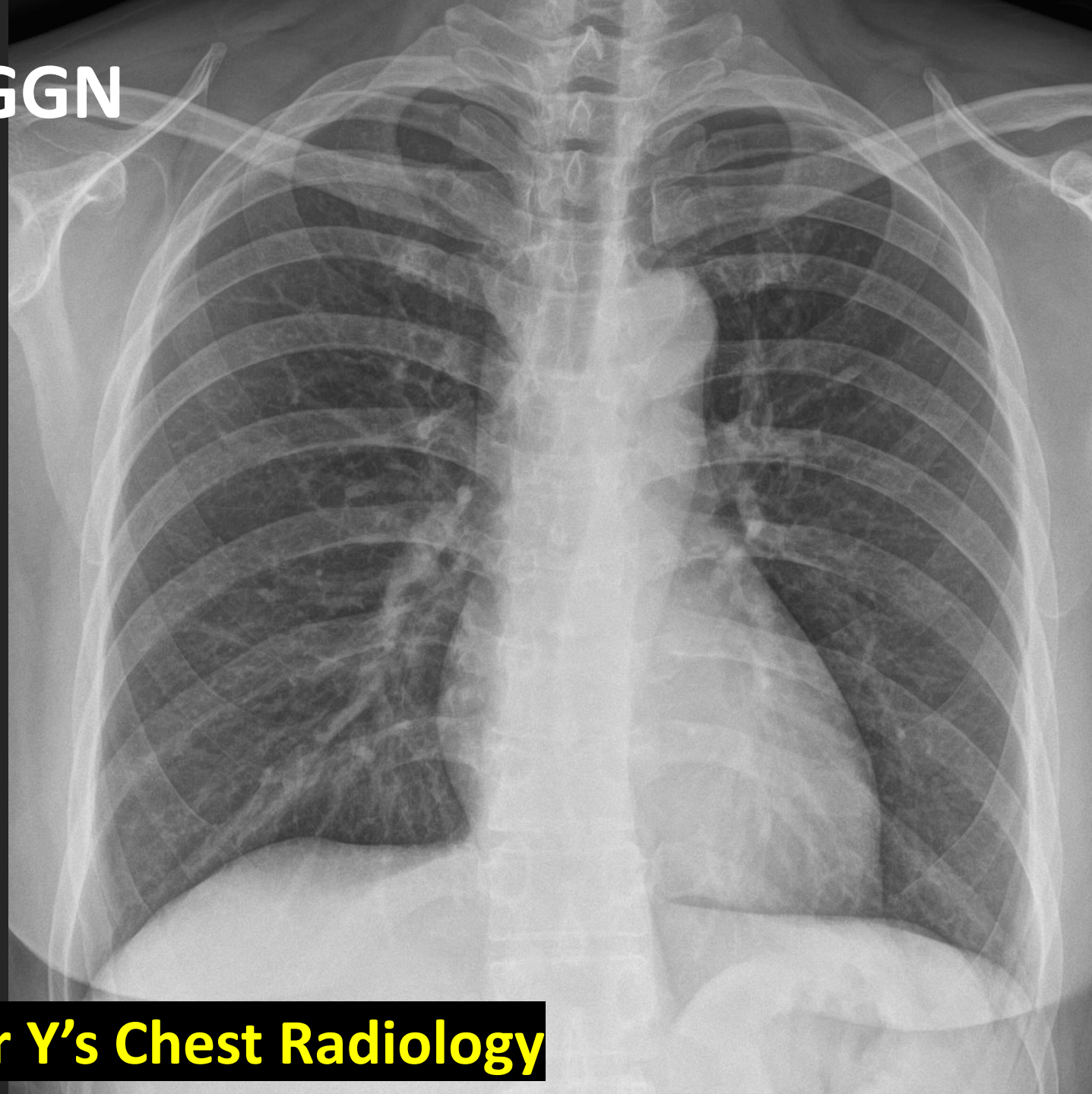


15 MA



Let's Enjoy 닥터 와이 폐영상

# History of GGN

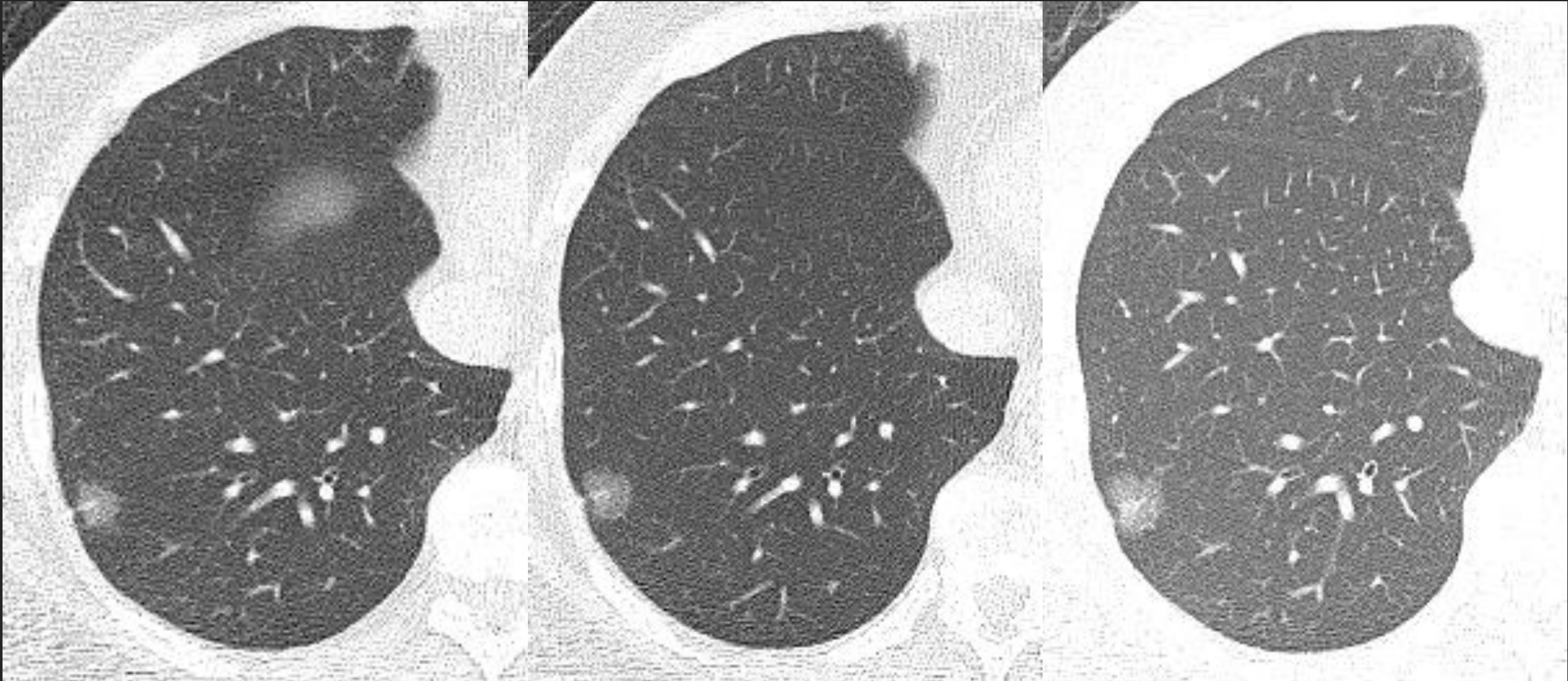


**Let's Enjoy Dr Y's Chest Radiology**

5 YA,

2 YA,

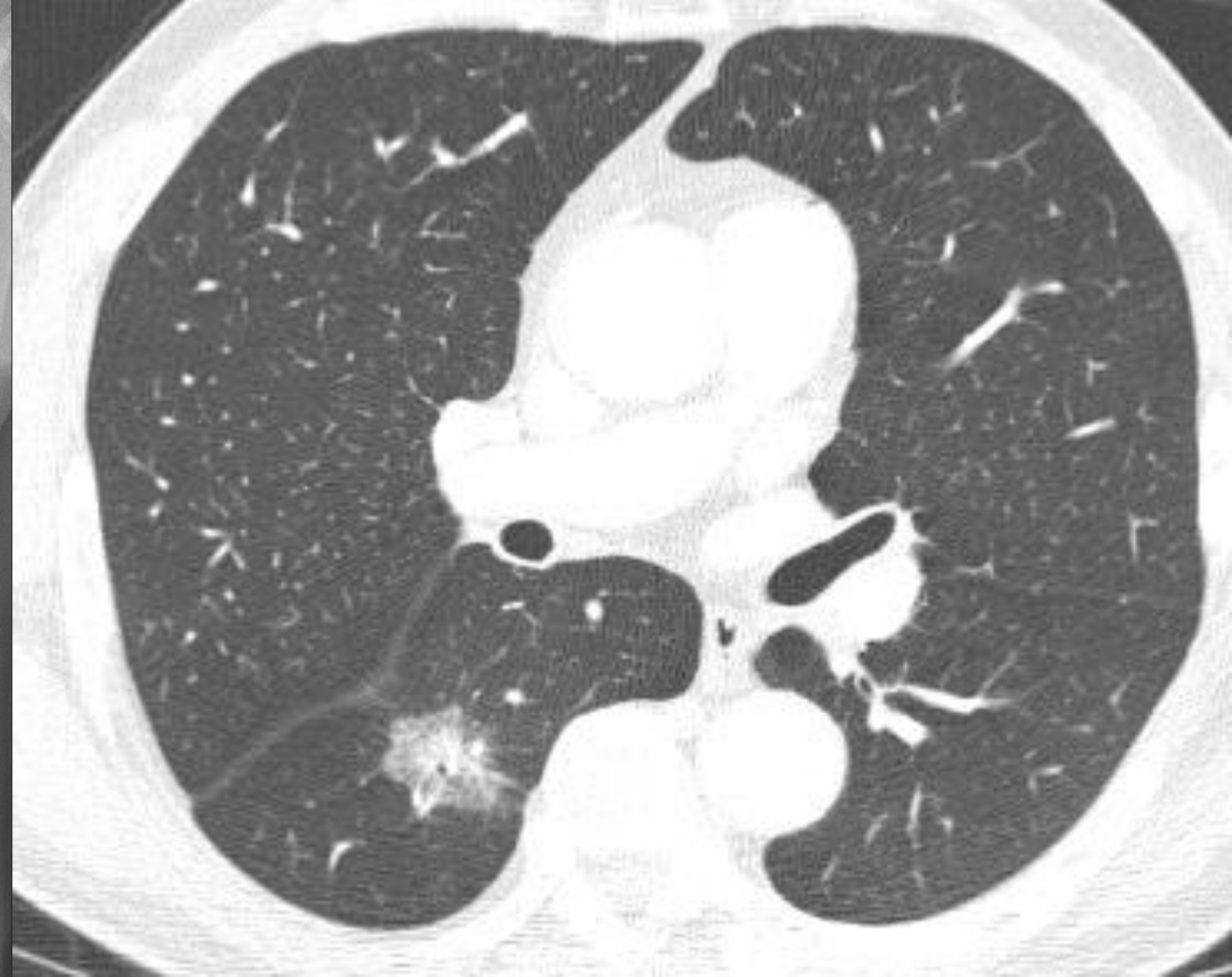now



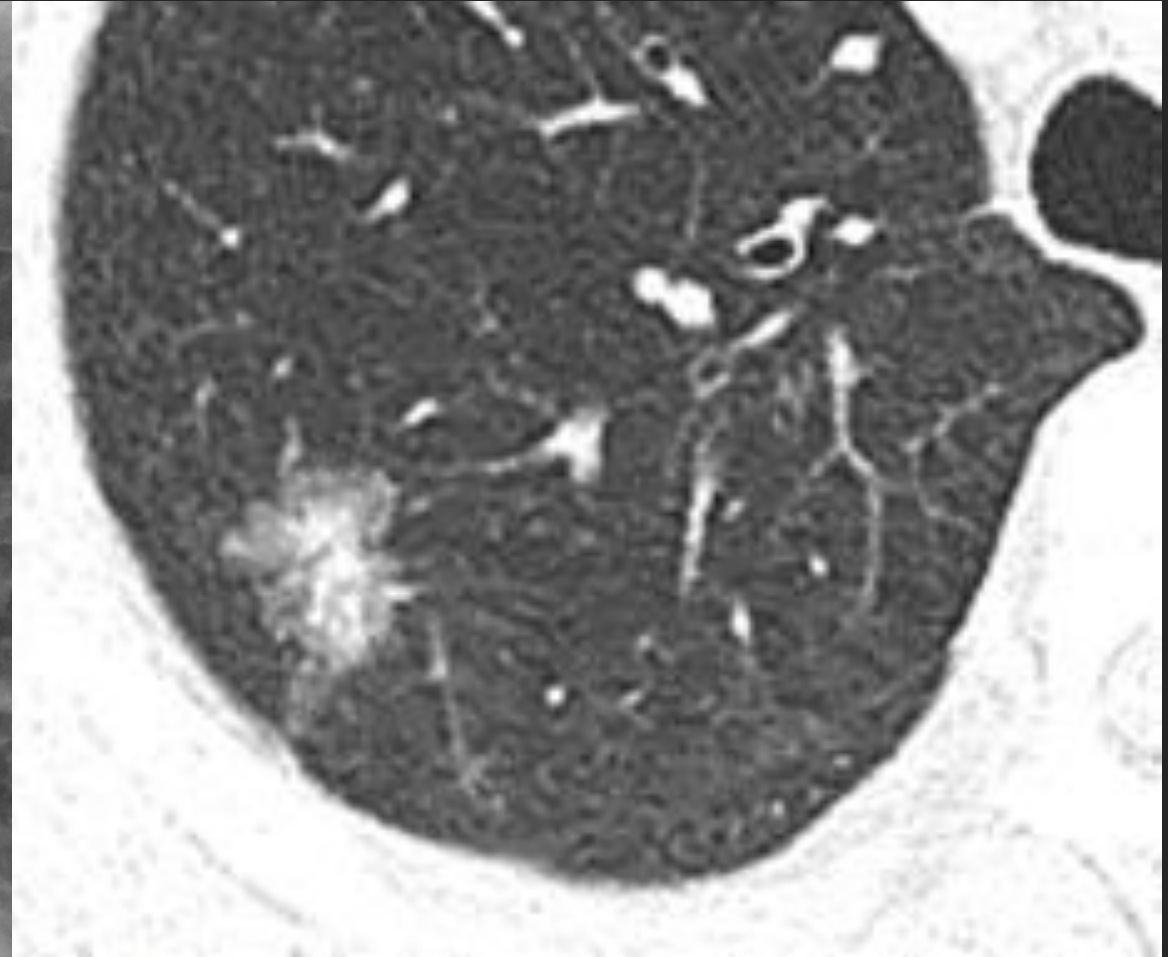
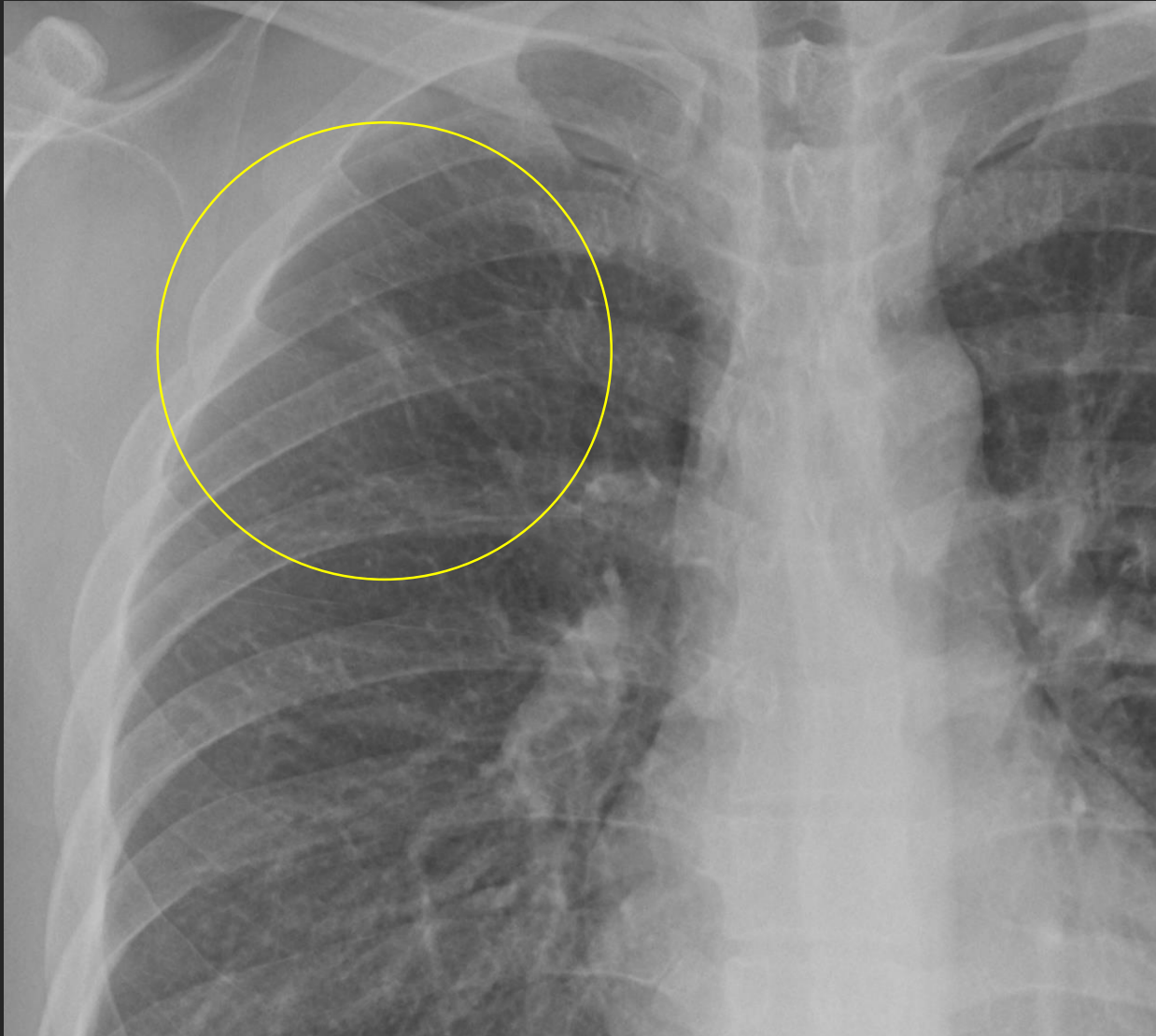**Let's Enjoy Dr Y's Chest Radiology**

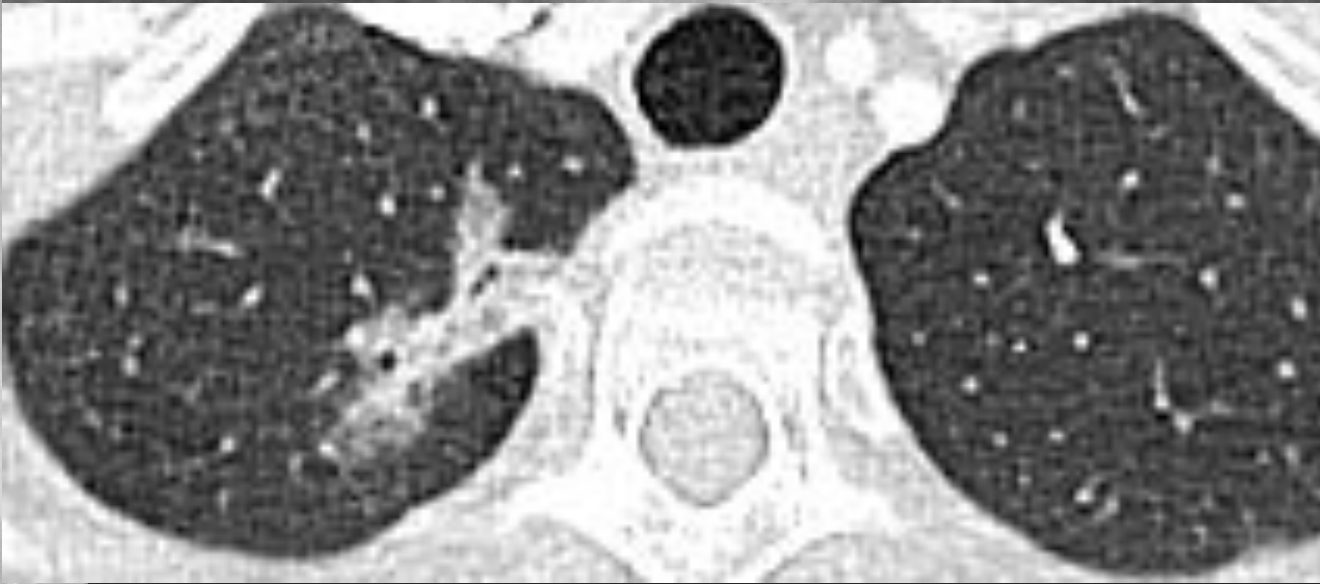
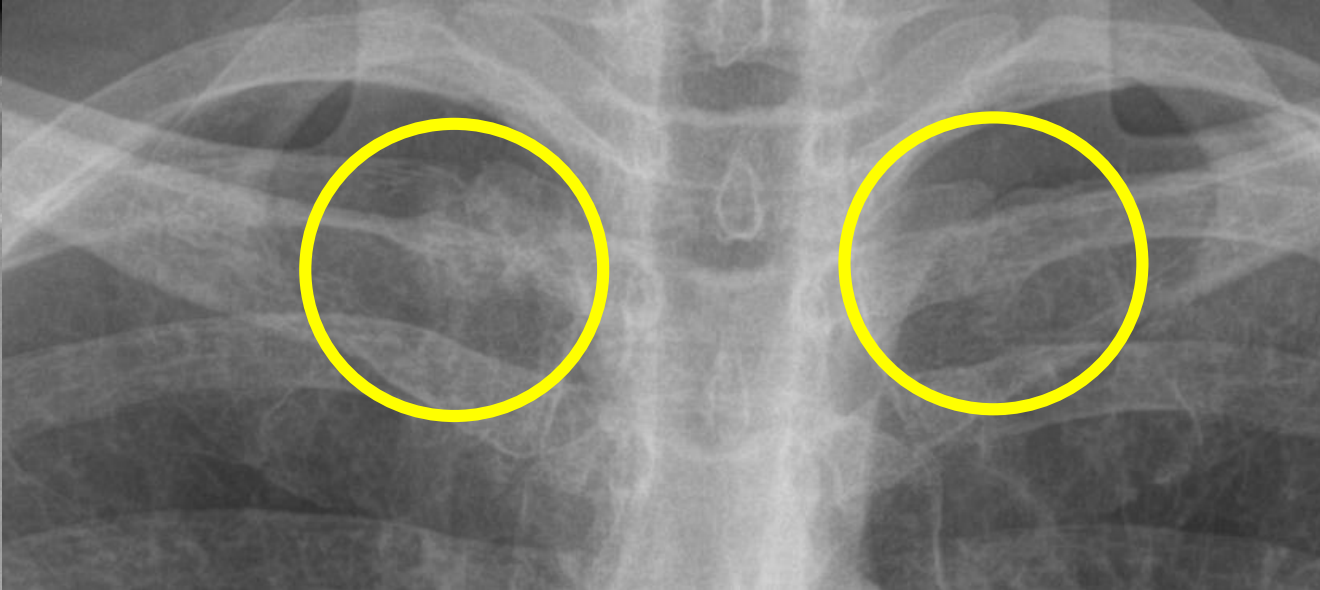
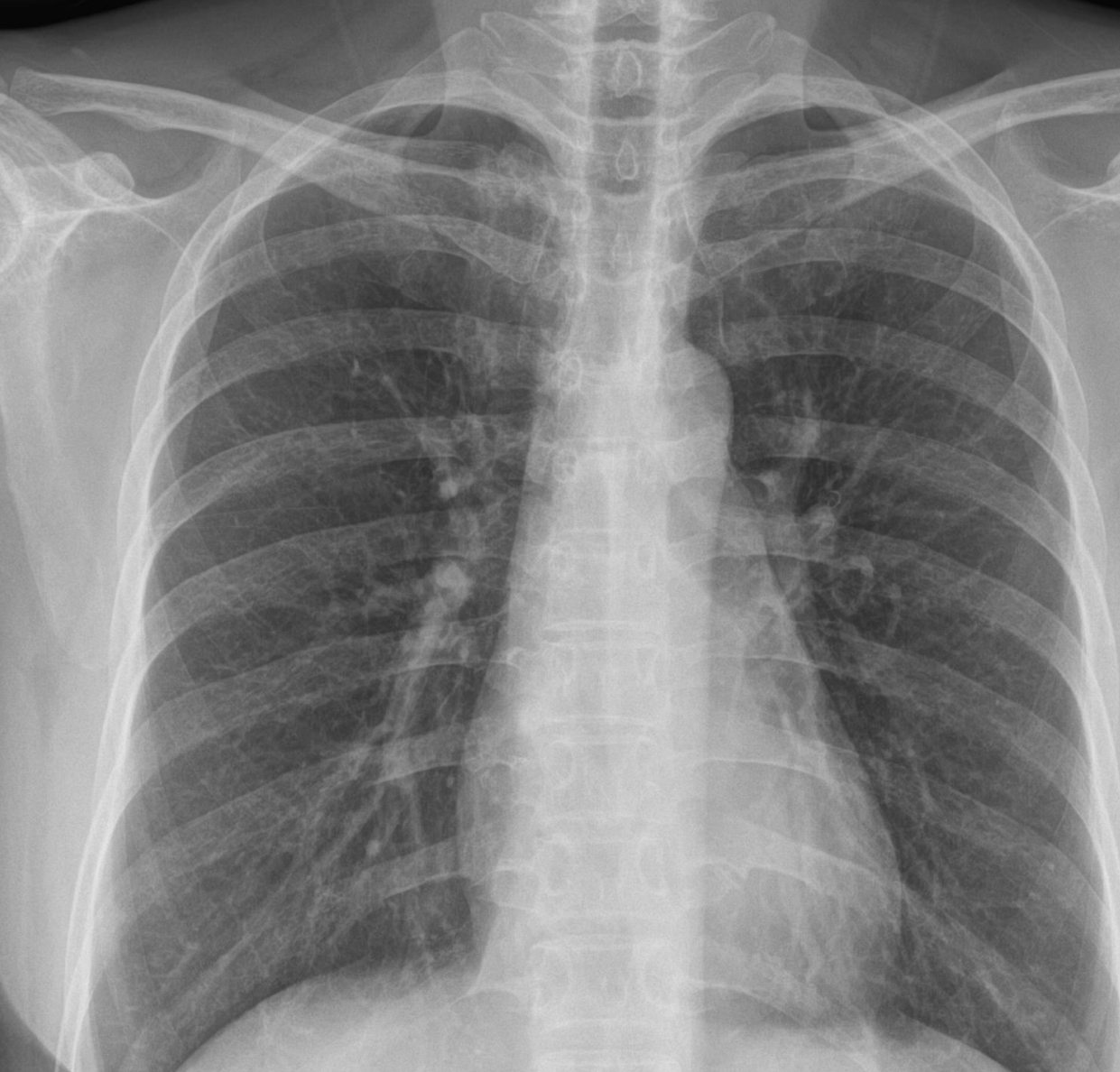**GGN**

**Let's Enjoy 닥터 와이 폐영상**



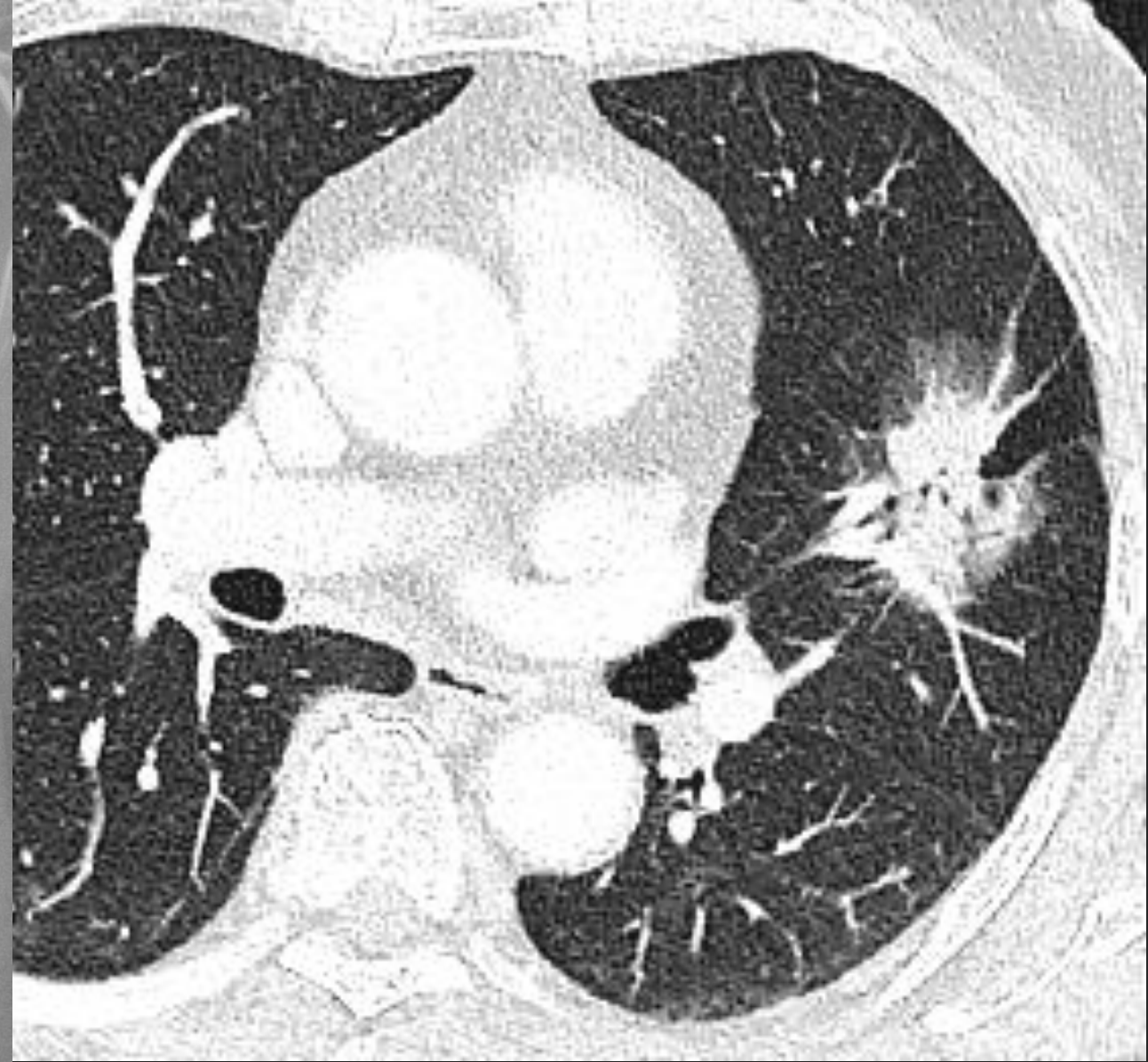
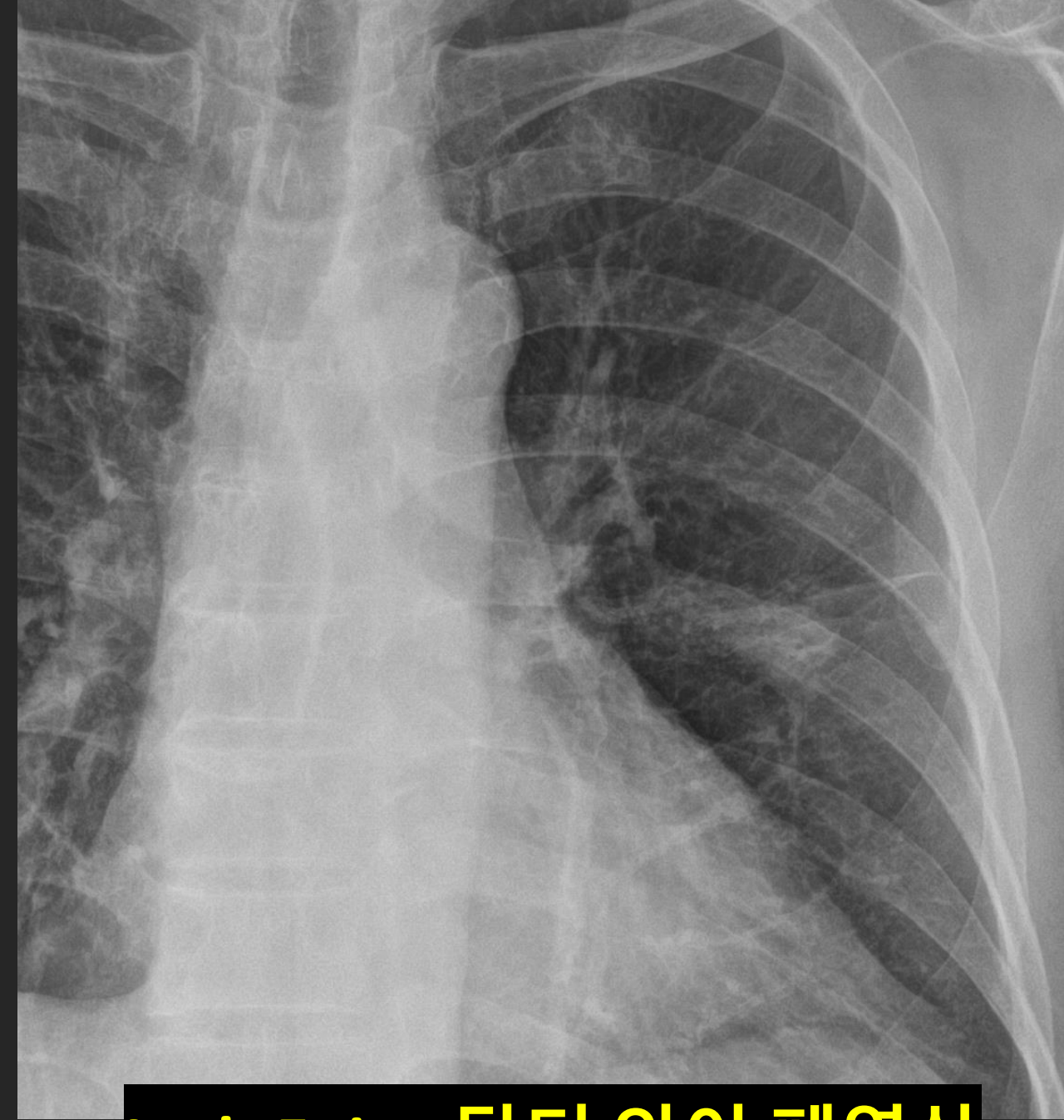
# Part solid nodule, adenocarcinoma, RUL





**Apex, GGN Adenocarcinoma vs. TB**

**Let's Enjoy 닥터 와이 폐영상**



**Let's Enjoy 닥터 와이 폐영상**

# 순서

- A. Central type
- B. Peripheral type
- C. “Missed” lung cancer
- D. New or Grow : 무섭다**

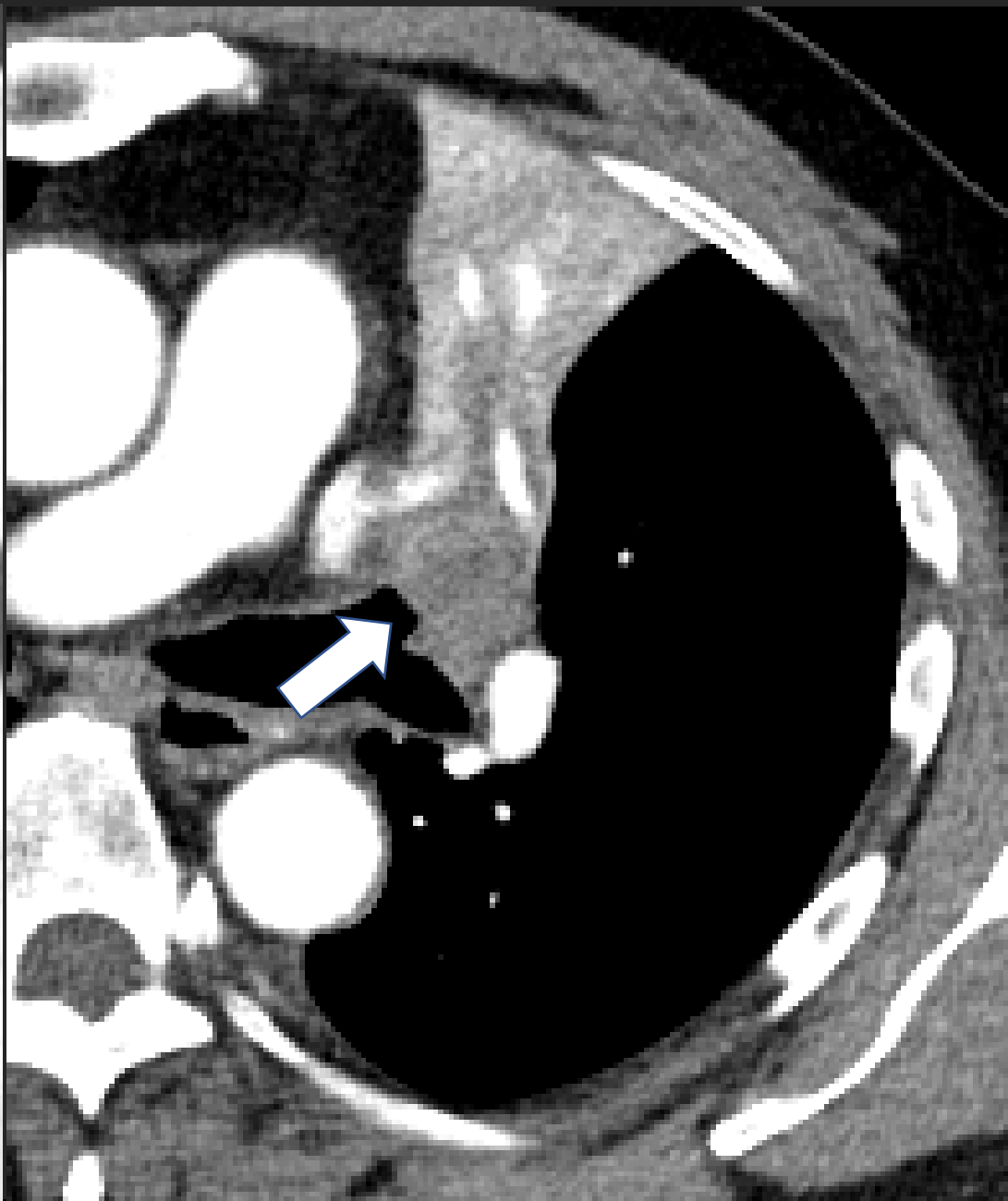
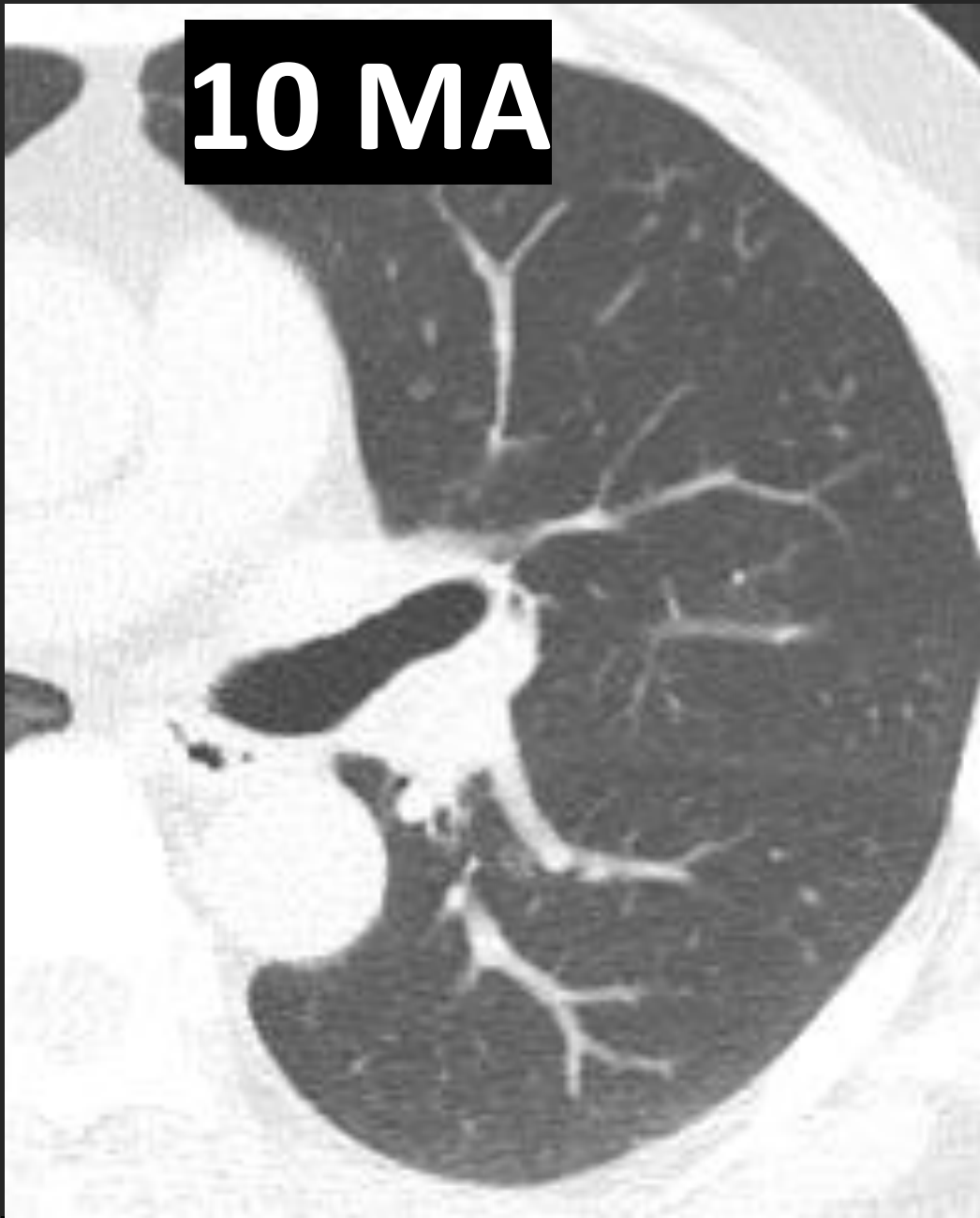

人命在天：禁煙

7 MA

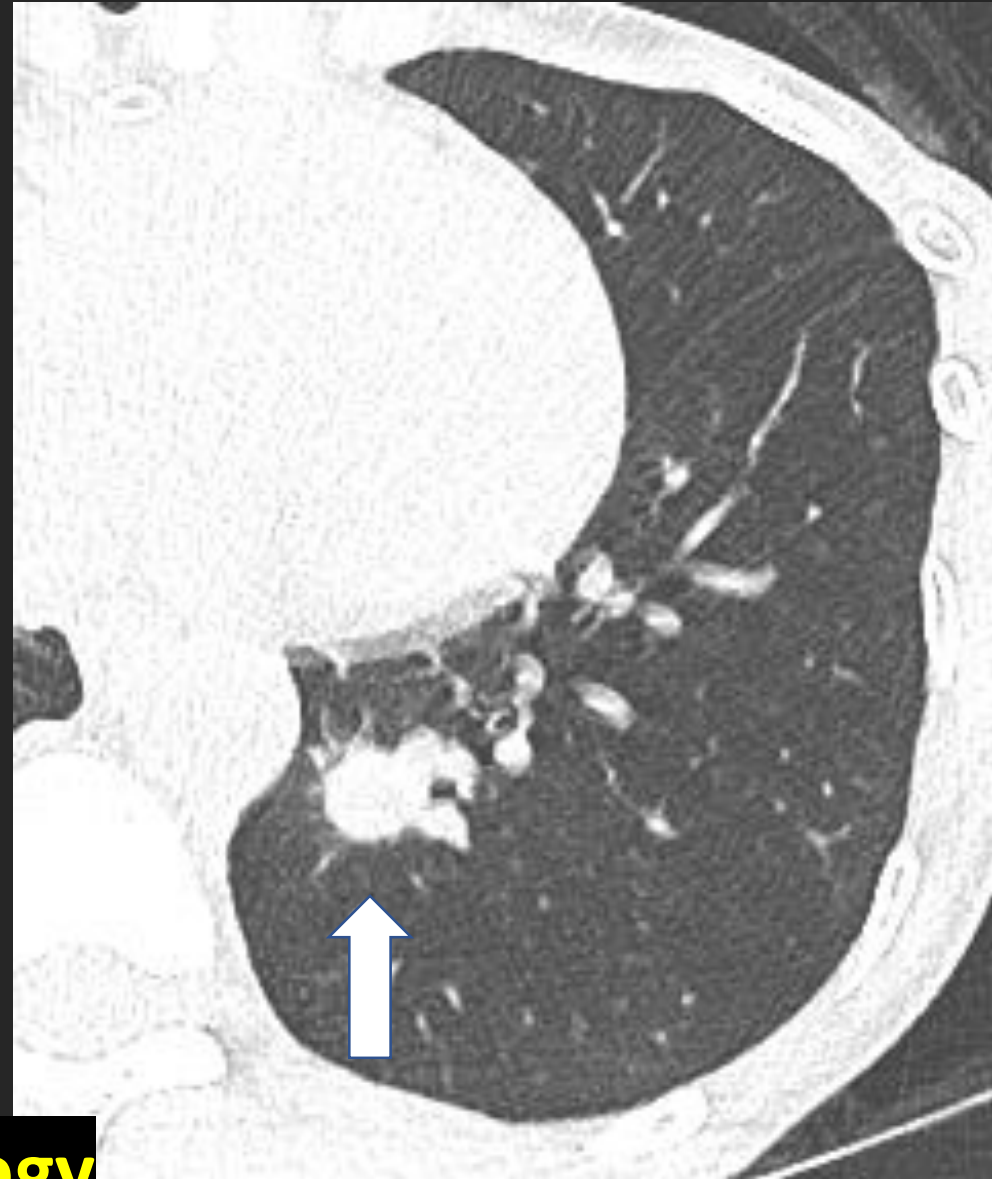
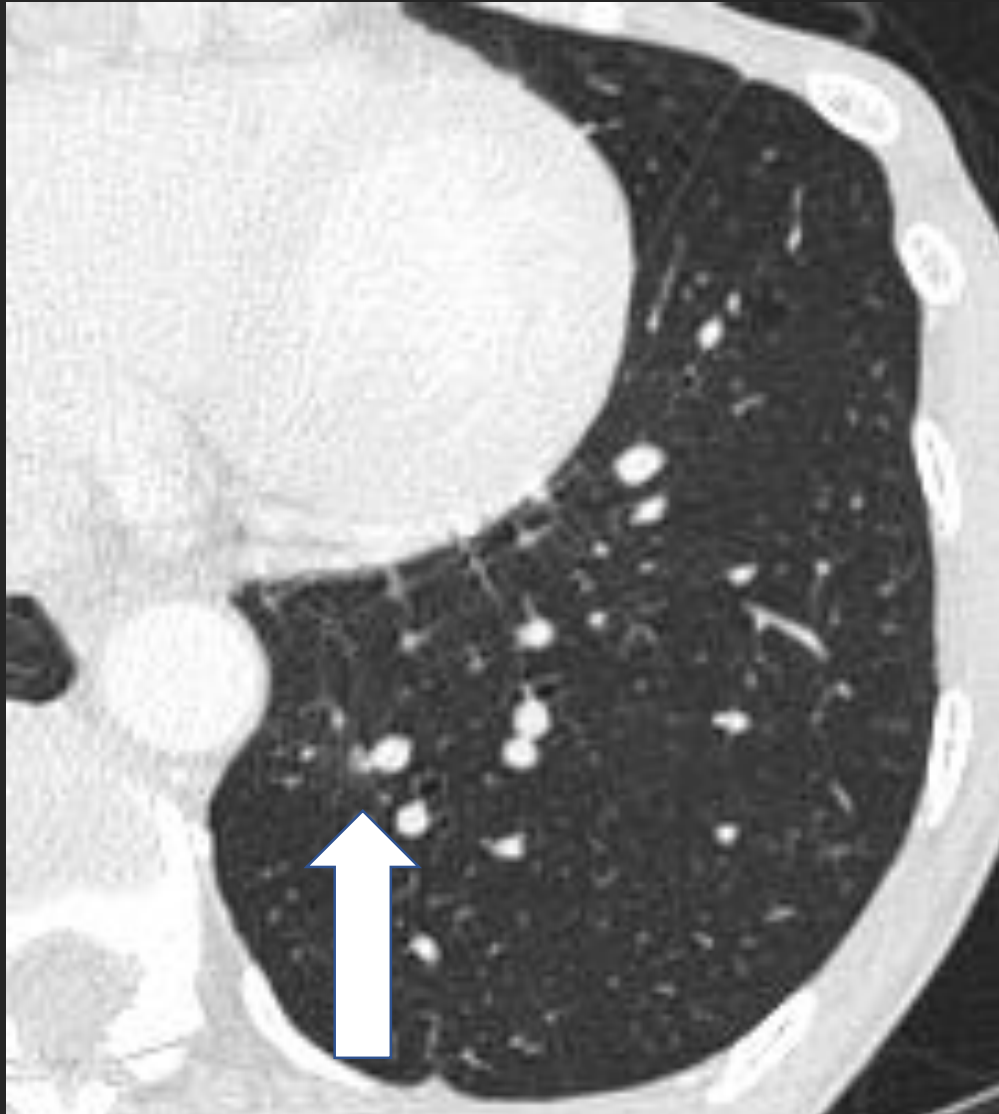Let's Enjoy 닥터 와이 폐영상

**10 MA**



**Let's Enjoy the Chest Radiograph with Dr Y Chest Radiology**

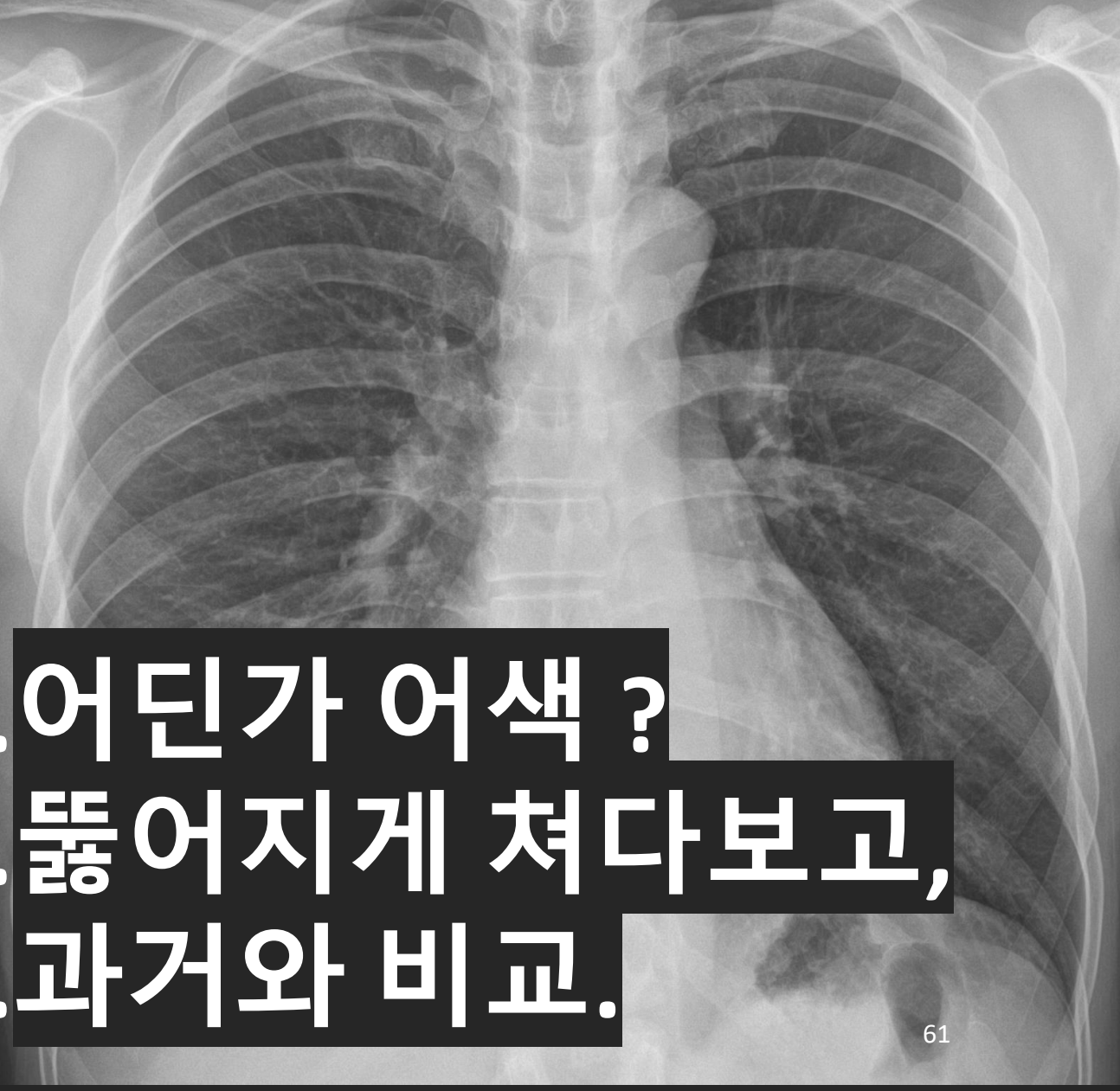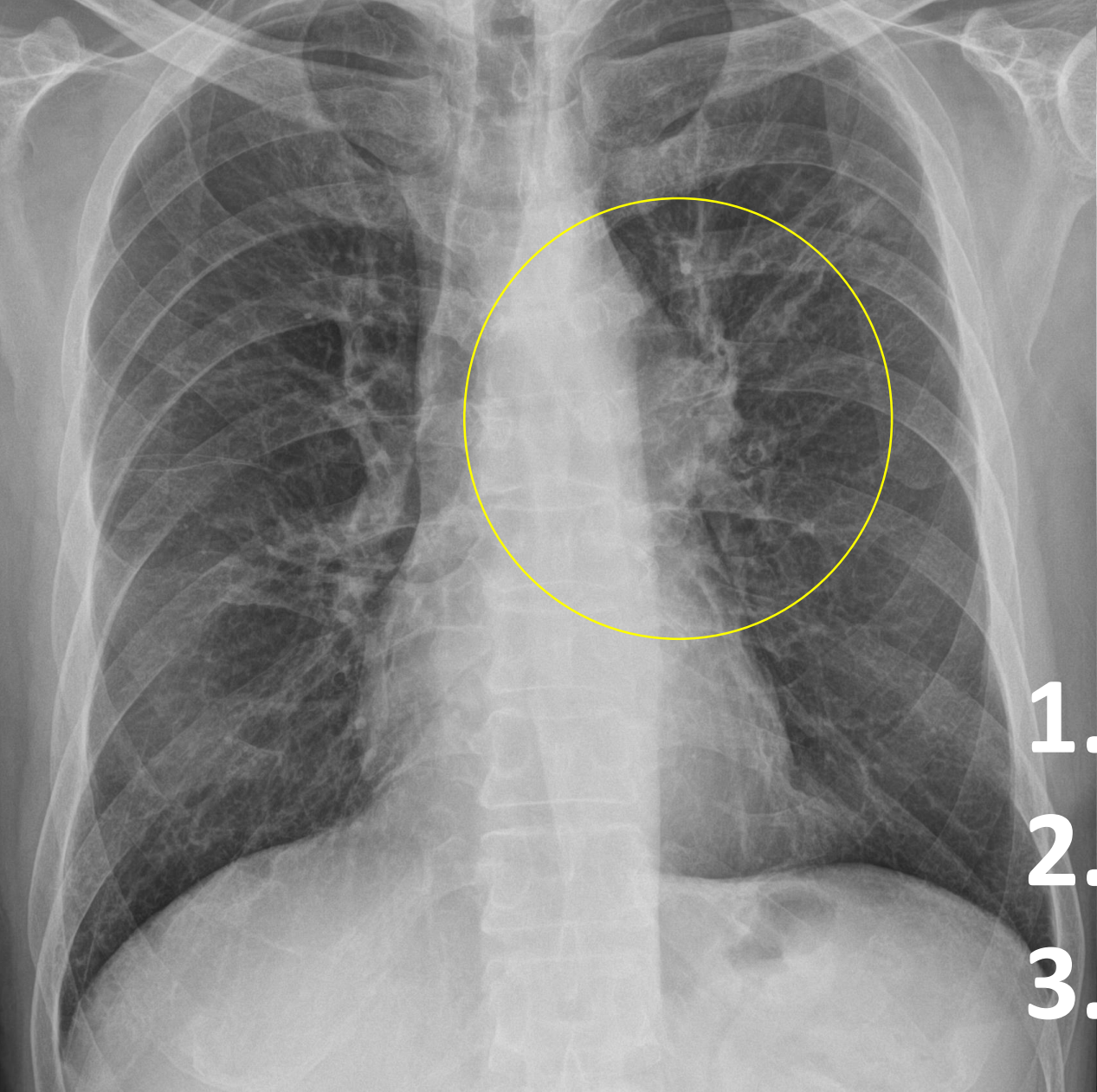
# Micronodule; 1 YA



**Let's Enjoy Dr Y's Chest Radiology**

폐암 診斷, 不如 禁煙  
폐암 治療, 不如 禁煙

# Take Home Message: “뭔가 어색하다”



1. 어딘가 어색 ?
2. 뚫어지게 쳐다보고,
3. 과거와 비교.